

Egbert J.D. Veen

sh

The ageing shoulder

uld

imaging, functional  
assessment and  
arthroscopic  
interventions

er



**The ageing shoulder:  
imaging, functional assessment  
and arthroscopic interventions**

Egbert J.D. Veen

Cover and design: Marije Esselink - Studio Neon

Layout: Douwe Oppewal

Printed by Ipskamp Printing, Enschede

Copyright 2022 © E.J.D. Veen

The Netherlands. All rights reserved. No parts of this thesis may be reproduced, stored in a retrieval system or transmitted in any form or by any means without permission of the author.

Publication of this thesis was kindly supported by: Annafonds I NOREF, Chipsoft, Medical School Medisch Spectrum Twente, Nederlandse Vereniging voor Arthroscopy, Nederlandse Orthopaedische Vereniging, SHARE research instituut Groningen, Onderzoeksbureau Deventer Ziekenhuis, Dutch Shoulder and Elbow Society, Egbert B.V., Coöperatie Orthopaedie Twente, MSC Zorg Beltstraat, FysioHolland, Fysiotherapie Oost-Nederland, Schouder Netwerk Twente.





rijksuniversiteit  
groningen

# **The ageing shoulder: imaging, functional assessment and arthroscopic interventions**

**Proefschrift**

ter verkrijging van de graad van doctor aan de  
Rijksuniversiteit Groningen  
op gezag van de  
rector magnificus prof. dr. C. Wijmenga  
en volgens besluit van het College voor Promoties.

De openbare verdediging zal plaatsvinden op

woensdag 16 februari 2022 om 14.30 uur

door

**Egbert Jan David Veen**

geboren op 4 november 1984  
te Almelo

**Promotores**

Prof. dr. R.L. Diercks

Dr. M. Stevens

**Copromotor**

Dr. C.T. Koorevaar

**Beoordelingscommissie**

Prof. dr. P.C. Jutte

Prof. dr. R.G.H.H. Nelissen

Prof. dr. H.E.J. Veeger

# TABLE OF CONTENTS

<b>Introduction</b>	9
<b>Chapter 1.</b> General introduction, aims, and outline of thesis	11
<b>Chapter 2.</b> Background	17
<b>Part 1: Ageing of the acromioclavicular joint</b>	27
<b>Chapter 3.</b> Predictive findings on magnetic resonance imaging in patients with symptomatic acromioclavicular osteoarthritis.	29
<b>Part 2: Ageing of the rotator cuff: functional analysis of patients with degenerative rotator cuff tears, and surgery of the long head of biceps tendon</b>	45
<b>Chapter 4.</b> Compensatory movement patterns are based on abnormal activity of the biceps brachii and posterior deltoid muscles in patients with symptomatic rotator cuff tears	47
<b>Chapter 5.</b> Long head of biceps tendon tenotomy in patients with degenerative rotator cuff tears: mid-term clinical results and prognostic factors.	69
<b>Chapter 6.</b> Biceps autograft augmentation for rotator cuff repair. A systematic review	85
<b>Chapter 7.</b> Using the long head of biceps tendon autograft as an anatomical reconstruction of the rotator cable: an arthroscopic technique for patients with massive rotator cuff tears	101
<b>Chapter 8.</b> The results of using a tendon autograft as a new rotator cable for patients with a massive rotator cuff tear: a comparative outcome analysis	113
<b>Part 3: Trends and controversies in the treatment of the ageing shoulder</b>	129
<b>Chapter 9.</b> Effect of implementation of the Clinical Practice Guideline for diagnosis and treatment of SubAcromial Pain Syndrome in the Netherlands	131
<b>Chapter 10.</b> Controversies in literature on treatment of rotator cuff tears	145
<b>Chapter 11.</b> General discussion	151
<b>Chapter 12.</b> Summary/Nederlandse samenvatting	163
Acknowledgments/Dankwoord	172
About the author	175
List of publications and presentations	176
Research Institute Share, recent theses	180






*“The art of operating is possible in part by habit, skills add a bit of excellence on top and everyone can achieve this art within a very short time. However, performing surgery in the right place and at the right time, knowing when it is necessary or if it can be avoided, the conditions that effect success or failure, the changes of plan in surgery based on these conditions, the outcome to be expected and the means to obtaining these results as much as possible: These are the difficult aspects of the art of surgery and the elements that constitute its science.”*

René Leriche (1879-1955), French surgeon  
(1951) *La Philosophie de la chirurgie*, Paris: Flammarion



# introduction

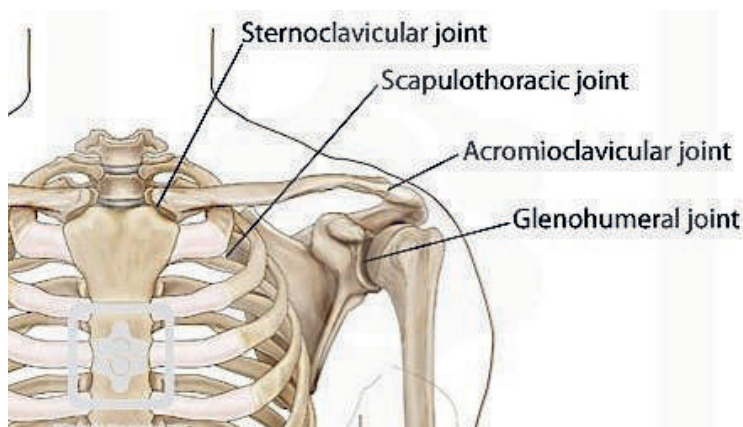




chapter 1

**General introduction, aims,  
and outline of thesis**

Tissue degeneration due to ageing starts relatively early in the shoulder joint compared to other joints and organs. As a result, degenerative shoulder conditions may start in middle age. The shoulder is composed of four closely connected joints (Figure 1) arranged in a complex anatomical relationship, conferring specific kinematics and resulting in specific pathological features with age.<sup>1,2</sup> As people get older they may develop varying degrees of arthrosis, tendinosis, and degenerative rotator cuff tears (RCT) in the shoulder,<sup>3</sup> which can potentially lead to pain or dysfunction.<sup>4,5</sup> The cause of these degenerative changes is likely to be multifactorial – related to a mix of genetic aspects, the environment, use/overuse and traumatic events. Together, these factors can make the shoulder difficult to examine, diagnose and treat.<sup>6,7</sup>



**Figure 1.** The four joints of the shoulder

Source: [www.shoulderdoc.co.uk](http://www.shoulderdoc.co.uk)

With an ageing population worldwide, the number of age-related shoulder complaints is increasing.<sup>8,9</sup> Ageing patients are remaining active and are demanding higher levels of function. This is increasing the demand for higher-quality diagnostic and therapeutic modalities for age-related pathologies of the shoulder.<sup>10</sup> The emergence of new technologies and techniques offers a multitude of surgical and non-surgical options for managing these age-related changes, especially in the treatment of RCTs. However, outcomes of each modality are affected by a variety of factors, and the challenge to the orthopedic surgeon is to provide the best possible individualized management of each patient.<sup>11</sup>

## AIM AND OUTLINE

The overall aim of this thesis is to study the functional and radiological changes that occur in the ageing shoulder and to assess operative treatment options for certain age-related shoulder pathologies. The studies described in the thesis aim to evaluate imaging modalities, functional assessment, and surgical techniques and their trends in the treatment of the ageing shoulder.

First, **Chapter 2** provides a brief overview of the unique anatomy and biomechanics of the shoulder, in order to appreciate the different patterns of ageing. Ongoing controversies in imaging, clinical testing, and existing and trending treatments of different pathologies around the shoulder are subsequently introduced.

### Part 1. Ageing of the acromioclavicular joint

The study in Part 1 of this thesis focuses on the ageing acromioclavicular (AC) joint: correlating clinical findings to radiological changes on MRI demonstrated in the degenerative AC joint. **Chapter 3** presents a study comparing MRI of patients with symptomatic AC osteoarthritis to a cohort of patients with subacromial pain syndrome (SAPS) and without clinical signs of AC osteoarthritis. Several predictive findings are evaluated, such as the presence of bone edema and joint distension to help in clinical decision-making.

### Part 2. Ageing of the rotator cuff: functional analysis and evaluation of established and novel surgical techniques

Part 2 of the thesis strives to provide insight into the functional changes seen in patients with an ageing rotator cuff and the treatment options available. **Chapter 4** elucidates the changes in activity of muscles of the shoulder girdle that occur when RCTs force patients to use compensatory movement patterns. Patients and controls were assessed while performing activities of daily living with registration of time, video and EMG of 10 different muscles around the shoulder.

One of the options in patients with a painful shoulder and an RCT who are not eligible for rotator cuff repair is to perform a tenotomy of the LHBT (long head of biceps tendon). In **Chapter 5** we present the clinical results of this technically simple arthroscopic treatment in a patient cohort. This procedure is often part of other arthroscopic shoulder surgery, but so far has not been described as an isolated treatment.

**Chapter 6** provides a systematic review of the use of the LHBT as an autograft to augment repair in the treatment of RCTs. This review presents several techniques and their clinical results as described in scientific literature. Based on the current available

techniques, **Chapter 7** proposes a novel technique of using the LHBT to reconstruct the rotator cable. The rotator cable is often involved in massive RCTs, but can be restored by incorporating the LHBT as a new cable. This study supplies a step-by-step guide, including several images. In **Chapter 8** this new technique of using the LHBT as an autograft for reconstruction of the rotator cable is evaluated in a pilot study presenting clinical and radiological outcomes. All patients were prospectively followed for at least one year, including a control MRI.

### **Part 3. Trends and controversies in the treatment of the ageing shoulder**

Part 3 gives an overview of the controversies and trends in the treatment of the ageing rotator cuff. In 2014 the Dutch Orthopedic Society established a clinical practice guideline for the diagnosis and treatment of subacromial pain syndrome (SAPS). In **Chapter 9** we evaluate the effect of this guideline on the current practice of general practitioners and orthopedic surgeons in the Netherlands. Trends in the conservative and operative treatment of SAPS and RCTs are studied by analyzing the Diagnosis Related Groupings declared by all Dutch hospitals. As the results of this study show, controversies remain amongst orthopedic surgeons as to the optimal treatment for degenerative RCTs.

**Chapter 10** discusses the latest studies on the treatment of RCTs, presenting them as a *pro et contra* of rotator cuff tear surgery. The thesis ends with a general discussion in **Chapter 11**, offering future perspectives on shoulder-related research.



## REFERENCES

1. Veeger, H. E. J., & Van Der Helm, F. C. T. (2007). Shoulder function: the perfect compromise between mobility and stability. *Journal of biomechanics*, 40(10), 2119-2129.
2. Lefèvre-Colau MM, Nguyen C, Palazzo C, Srouf F, Paris G, Vuillemin V ... & Roren A (2018). Kinematic patterns in normal and degenerative shoulders. Part II: Review of 3-D scapular kinematic patterns in patients with shoulder pain, and clinical implications. *Annals of physical and rehabilitation medicine*, 61(1), 46-53.
3. Gumina S, Carbone S, Campagna V, Candela V, Sacchetti FM & Giannicola G (2013). The impact of ageing on rotator cuff tear size. *Musculoskeletal surgery*, 97(1), 69-72.
4. Safran O, Schroeder J, Bloom R, Weil Y & Milgrom C. (2011). Natural history of nonoperatively treated symptomatic rotator cuff tears in patients 60 years old or younger. *The American journal of sports medicine*, 39(4), 710-714.
5. Bonsell S, Pearsall IV A, Heitman RJ, Helms CA, Major NM & Speer KP (2000). The relationship of age, gender, and degenerative changes observed on radiographs of the shoulder in asymptomatic individuals. *The Journal of bone and joint surgery. British volume*, 82(8), 1135-1139.
6. Lewis JS, Tennent TD, MacAuley D & Best T (2007). How effective are diagnostic tests for the assessment of rotator cuff disease of the shoulder. *Evidence Based Sports Medicine*, 327, 360.
7. Zanetti M & Hodler J (2000). Imaging of degenerative and posttraumatic disease in the shoulder joint with ultrasound. *European journal of radiology*, 35(2), 119-125.
8. Luime JJ, Koes BW, Hendriksen IJM, Burdorf A, Verhagen AP, Miedema HS & Verhaar JAN (2004). Prevalence and incidence of shoulder pain in the general population; a systematic review. *Scandinavian journal of rheumatology*, 33(2), 73-81.
9. Greving K, Dorrestijn O, Winters JC, Groenhof F , van der Meer K. Stevens M & Diercks RL (2012). Incidence, prevalence, and consultation rates of shoulder complaints in general practice. *Scandinavian journal of rheumatology*, 41(2), 150-155.
10. Cadogan A, Laslett M, Hing WA, McNair PJ & Coates MH (2011). A prospective study of shoulder pain in primary care: prevalence of imaged pathology and response to guided diagnostic blocks. *BMC musculoskeletal disorders*, 12(1), 1-18.
11. Longo UG, Ambrogioni LR, Candela V, Berton A, Carnevale A, Schena E, & Denaro V (2021). Conservative versus surgical management for patients with rotator cuff tears: a systematic review and META-analysis. *BMC Musculoskeletal Disorders*, 22(1), 1-10.



chapter 2

# Background

This chapter gives a brief overview of the relevant anatomy of the shoulder, which is needed to understand the further description of characteristic patterns of ageing of the different bone, joint, tendon, and muscle structures of the shoulder joint. Some treatment options are also discussed. This will serve as a foundation for a deeper understanding of the different studies of the subsequent chapters.

## GENERAL ANATOMY

The unique form and function of the human shoulder is due to the evolution from quadruped to biped anatomy. The shoulder, including the scapula, migrated from an in-line position of the thorax (four limbs, running in line) to a posterior placement on the thorax, enabling the function of the shoulder with its wide range of motion as it is nowadays. This outstanding function comes from the glenohumeral joint, which is the key joint of the shoulder. It is composed of a rather large humeral head and a relatively small socket, the glenoid, which enables a very large range of motion, such as flexion, extension, abduction, adduction and rotation, in three anatomical planes.<sup>1</sup> The rotator cuff muscles (supraspinatus, infraspinatus, subscapularis, teres minor) originate from the scapula and coalesce with each other to form the multilayered rotator cuff tendon, which cups to closely contain the humeral head.<sup>1,2</sup> Interestingly, the rotator cuff is only seen in humans, advanced primates and tree kangaroos,<sup>3</sup> and helps merge and spread the forces of the several muscles onto the humeral head in order to centralize the humeral head during movement.<sup>4</sup>

Another result of the advanced evolution of the shoulder is a transverse thickening of the lateral rotator cuff: the rotator cable.<sup>5</sup> Distinct fibrous tissue can be found which originates from the deep layer of the coracohumeral ligament and moves along the perpendicular axis of supraspinatus and infraspinatus tendon fibres.<sup>2</sup>

Part of the upper limb is also the m. biceps brachii, whose long head passes through its groove to insert intra-articularly into the mobile superior labrum and glenoid. The biceps is known for its important role in elbow function, plus has a stabilizing and mild depressor effect on the humeral head.<sup>6</sup> The biceps tendon is in fact a vestigial structure whose function is not yet fully unraveled.

## PATHOANATOMICAL CHANGES AND CHALLENGES IN THE TREATMENT OF THE AGEING SHOULDER

### AC joint

During ageing typical degenerative patterns are found in the different parts of the shoulder. The AC joint is often osteoarthritic – for age, overuse, posttraumatic or idiopathic reasons – and can show different degrees of typical arthritic changes that include synovitis, osteophytes, sclerosis, joint-space narrowing and cyst formation. These changes can arise at an early age already, although only a minority will develop clinical symptoms.

This mechanism of developing AC joint osteoarthritis is not fully understood, although anatomic studies in twins indicate that 20% is accounted for by genetics and that environmental factors have the greatest impact.<sup>7</sup> Diagnosis of AC osteoarthritis can be challenging, given the lack of specificity and sensitivity with positive physical examination findings and the variable nature of AC joint pain.<sup>8</sup> Conventional X-rays only show bony changes. An MRI is often used for further imaging and can show different signs, such as bone edema, capsular thickening and compression of the AC joint on the rotator cuff, but it is uncertain whether any of the changes found can be related to clinical signs. These signs can be found locally, and some – like osteophytes – even extend into the subacromial space. Taking these factors into consideration, radiological support for diagnosing symptomatic AC joint osteoarthritis might be helpful.

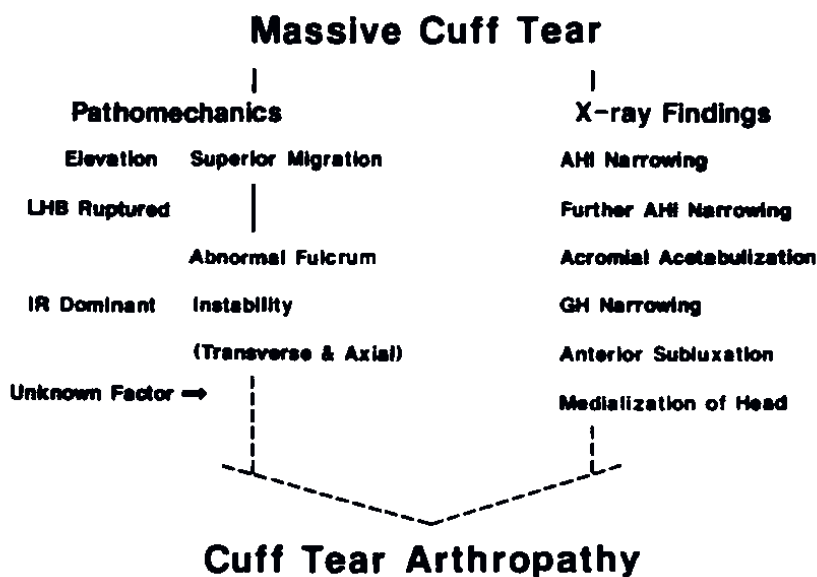
### Rotator cuff disease

The rotator cuff, composed of tendons of the subscapularis, supraspinatus, infraspinatus and teres minor muscles, can show degeneration by developing tendinopathy, partial tears and full-thickness tears, and in time this can lead to a cuff tear arthropathy.

#### *Degenerative rotator cuff tendinopathy*

A direct cause of shoulder pain cannot always be found. Different pathologies with overlapping clinical presentations can develop which may complicate diagnosing, and not every degenerative abnormality gives rise to complaints. And still, when trying to find an anatomical cause of shoulder complaints, especially with use of ultrasound and MRI, there can be overdiagnosing – i.e. defining a non-pathological radiological entity (“incidentaloma”) as pathological. By contrast, sometimes patients have shoulder pain in the absence of abnormalities. The term “impingement” was popularized by Charles Neer, implying a biomechanical explanation of the acromion impinging on the soft tissue of the cuff.<sup>9</sup> Analysis on a cellular level reveals a complex process of pathological changes in the collagen structure. This leads to thinning, disorientation and overall degeneration of the tendon, and is accompanied by fibroblast proliferation and expression of inflammatory cytokines.<sup>10</sup>

It is however uncertain to what extent these findings, also identified on imaging, account for symptom provocation. To this end, a new definition was recently developed: subacromial pain syndrome (SAPS), a typical clinical presentation of pain situated distally of the acromion, provoked on active and passive abduction, a painful arc and pain at night, with its highest incidence in the population around their fifth decade. Imaging can show tendinitis of the cuff and bursitis or partial cuff tears.



**Figure 1.** Original description by Hamada<sup>15</sup> of the natural course of massive rotator cuff tear leading to cuff tear arthropathy

### *Rotator cuff tears*

Typically degenerative rotator cuff tearing starts at the crescent area, a relative avascular zone between the rotator cable and the tuberosity. This can lead to either an anterosuperior or a posterosuperior tear. As all tendons join together on the enthesis it can be hard to define which tendons are involved, therefore these two main tear patterns are identified: anterosuperior, with involvement of the subscapularis and supraspinatus tendons, and posterosuperior, with involvement of the infraspinatus and supraspinatus tendons. Rotator cuff tears can respond well to conservative treatment, even without structural healing, and are defined as “functional rotator cuff tears”.<sup>11</sup> Biomechanical studies show the importance of the rotator cable as small tears can be well tolerated, but if this cable is torn increased regional tendon strain under physiological conditions can be found.<sup>12</sup> Larger tears can evolve into a massive rotator cuff tear (MRCT), which is defined as 2-3 tendons torn and/or >2-5 cm retraction, and which eventually could lead to a pseudoparalysis (inability to actively elevate the arm above 90°).<sup>13</sup> In

this stage a rotator cuff tear (RCT) is disabling and repairs are challenging. As a result, tendons retract to the glenoid, the muscle belly atrophies, and fatty infiltration is seen. In the past, EMG studies used testing environments, performing static movements with isometric contractions to evaluate muscle activities of shoulders with an RCT. But as a more patient-centered approach is increasingly appreciated, objective measures are needed with patients performing activities of daily living such as the Functional Impairment Test-Hand and Neck/Shoulder/Arm (FIT-HaNSA).<sup>14</sup>

### *Cuff tear arthropathy*

An RCT left untreated may lead to an increase of the tear involving the whole rotator cuff – an MRCT. In this situation the humeral head translates superiorly, the fulcrum of the remaining cuff is insufficient, and this can ultimately create a neoarticulation with acromial acetabulization<sup>15</sup> and spontaneous tenodesis of the long head of biceps tendon (LHBT).<sup>16</sup> This specific pattern is named “cuff tear arthropathy” and should be distinguished from primary glenohumeral osteoarthritis. Hamada<sup>15</sup> described the specific pattern of cuff tear arthropathy already in 1990, correlating the pathomechanics to radiological findings (as depicted in Figure 1).

### **Long head of biceps tendinopathy**

The biceps tendon, which is one of the few tendons in the human body that runs intra-articularly, can be the only structure left between the humeral head and the acromion in case of a full-size RCT. This results in tendinopathy and enlargement of the biceps tendon (hourglass deformity). Observations also rapport about the compensation by the biceps muscle for an inadequate rotator cuff function.<sup>17,18</sup> When the subscapularis tendon is (partly) torn, the biceps tendon can dislocate from its groove, which is normally covered by this subscapularis tendon, and cause pain and dysfunction.<sup>19</sup> Spontaneous (partial) ruptures can occur too in these degenerated or overused biceps tendons.

As evolution changed the role of this muscle, it is sometimes called “an unimportant vestigial structure unless something goes wrong with it”.<sup>20</sup>

## **TREATMENT**

### **Treatment of degenerative rotator cuff tendinopathy**

The subacromial “impingement” dogma resulted in a popularization of surgery to decompress the anterior acromion. However, emerging literature shows limited benefit from this treatment.<sup>21</sup> Also, Neer’s explanation could not be substantiated in imaging or pathoanatomic studies.<sup>22</sup> This leaves conservative measures such as explanation, adaptation and life modification, pain medication, steroid injections and physiotherapy

as the main treatment options. In most cases this leads to successful reduction of symptoms. No benefit from surgery was seen over conservative treatment as stipulated in the Dutch clinical practice guideline for diagnosis and treatment of subacromial pain syndrome.<sup>23</sup> Old habits die hard though, and even after the presentation of this and similar guidelines in different countries, this type of surgery is still performed.

### Treatment of degenerative rotator cuff tears

Similarly to treatment for tendinopathy, conservative treatment for RCTs, including physiotherapy, analgesia and/or steroid injections, is often sufficient to relieve pain and regain function. When conservative treatment fails it can be decided to offer surgical treatment such as an (arthroscopic) rotator cuff repair. Both options show significant improvement at 1 year.<sup>24</sup> Looking at 10 years a better result is only seen after surgery in small- to medium-sized tears,<sup>25</sup> although the measures did not exceed the minimal clinically important difference. Still, after a primary rotator cuff repair for degenerative RCTs, overall retear rate remains around 30% (20-70%).<sup>26,27</sup> It remains paradoxical that numbers of studies on RCTs are rising each year but most cited articles are of level IV quality.<sup>28,29,30</sup>

When rotator cuff repair does not seem possible, several surgical options are proposed which vary from symptomatic relief like debridement and solely cutting the biceps tendon to advancing the rotator cuff muscles, use of tendon transfers or grafts to reconstruct the cuff or the superior capsule, or ultimately joint replacement with a reversed shoulder arthroplasty – but none of the latter options restores normal shoulder function and intense rehabilitation is often required. Even then, outcome is variable. It seems that the unique function of the rotator cuff is difficult to reproduce or replace.<sup>31</sup>

As explained before, several biological changes take place in a degeneration rotator cuff tendon, leading to spontaneous ruptures. As a result, offering a mechanical solution (such as cuff repair) is likely to fail. Hence the high rate of re-tears after a cuff repair. Patient selection is therefore paramount to predicting successful outcome after surgery.

Several factors like tendon retraction, fatty infiltration of muscles and number of tendons involved all influence outcome after rotator cuff repair negatively, but age is known to be one of the most important.<sup>32</sup> Interestingly, even failed rotator cuff repairs show improved outcome.<sup>33</sup> Despite the development of new surgical techniques, the perfect solution remains elusive.

### Treatment of cuff tear arthropathy

The evolution from MCRT to cuff tear arthropathy can be categorized into five stages according to the Hamada classification<sup>34</sup> (Table 1), which gives some guidance for treatment options. For example, joint-preserving therapy, as mentioned before, is



deemed useful in stages 1, 2 and maybe 3. In case of advanced arthropathy (stages 4 and 5) only a joint replacement is appropriate.

**Table 1.** Status of the acromiohumeral space, glenohumeral joint, rotator cuff, and long head of the biceps according to grade in Hamada classification

Grade	Acromiohumeral space	Glenohumeral joint	Rotator cuff/LHB
1	AHI > 6 mm	Normal	Massive with LHB intact
2	AHI < 5 mm	Normal	Massive with LHB tear
3	Acetabulization	Normal	Massive with LHB tear
4	Acetabulization	Narrowed	Massive with LHB tear
5	Acetabulization	Humeral head collapse	Massive with LHB tear

AHI = acromiohumeral interval; LHB = long head of the biceps.  
Table from Brolin et al.<sup>35</sup>

### Treatment of long head of biceps tendinopathy

Already in 1936 Gilcreest reported on surgical treatment for LHBT; his patients were suffering from elongated and dislocating tendons.<sup>36</sup> In the late 20<sup>th</sup> century, when arthroscopic surgery of the shoulder became popular, the biceps tendon was often addressed in rotator cuff surgery. Studies report on benefits from tenotomy or tenodesis, but often performed in addition to other surgery such as rotator cuff repair or subacromial decompression.<sup>18</sup> Many subsequent studies show similar outcomes from treatments, with good effects. Less is known about the effect of solely cutting the tendon as a treatment in RCTs. If sacrificed, could the remnant of the LHBT not be of added value by using it to augment a rotator cuff repair? Although the positive effects are shown of treating the biceps tendon in patients with an RCT – implying a role in function and pain – less is known about the role of the LHBT in these tears. Earlier studies found an additional activation of the biceps muscle in patients with an RCT, suggesting an additional downforcing effect on the humeral head while tested in static conditions and compared to young individuals.<sup>37</sup> This mechanism is thought to cause some of the pain in patients with an RCT, but this has never been compared to an age-matched group in a functional setting. May the LHBT be playing an increasing role with age? Or is this due to a rotator cuff tear?

## IN CONCLUSION

As the shoulder joint ages, all structures in the shoulder girdle degenerate, such as the cartilage in the glenohumeral and AC joints, the rotator cuff tendons and the LHBT. All of them can cause pain, can lead to shoulder dysfunction, and often have overlap in clinical presentation. Correct diagnosing and subsequent treatment to deliver personalized medicine can therefore be challenging for physicians.


## REFERENCES

1. Bain GI, Phadnis J, Itoi E, Di Giacomo G, Sugaya H, Sonnabend DH, & McLean J (2019). Shoulder crane: a concept of suspension, stability, control and motion. *Journal of ISAKOS: Joint Disorders & Orthopaedic Sports Medicine*, 4(2), 63-70.
2. Huri G, Kaymakoglu M & Garbis N (2019). Rotator cable and rotator interval: anatomy, biomechanics and clinical importance. *EFORT open reviews*, 4(2), 56-62.
3. Sonnabend DH & Young AA (2009). Comparative anatomy of the rotator cuff. *The Journal of bone and joint surgery. British volume*, 91(12), 1632-1637.
4. Rahu, M., Kolts, I., Põldoja, E. & Kask, K. (2017). Rotator cuff tendon connections with the rotator cable. *Knee Surgery, Sports Traumatology, Arthroscopy*, 25(7), 2047-2050.
5. Burkhart SS, Esch JC & Jolson RS (1993). The rotator crescent and rotator cable: an anatomic description of the shoulder's "suspension bridge". *Arthroscopy: The Journal of Arthroscopic & Related Surgery*, 9(6), 611-616.
6. Rodosky MW, Harner CD & Fu FH (1994). The role of the long head of the biceps muscle and superior glenoid labrum in anterior stability of the shoulder. *The American journal of sports medicine*, 22(1), 121-130.
7. Candela V, Villani C, Preziosi Standoli J, Scacchi M & Gumina S (2021). AC joint osteoarthritis: The role of genetics. An MRI evaluation of asymptomatic elderly twins. *Journal of Anatomy*, 238(4), 1023-1027.
8. Mall NA, Foley E, Chalmers PN, Cole BJ, Romeo AA & Bach Jr BR (2013). Degenerative joint disease of the acromioclavicular joint: a review. *The American journal of sports medicine*, 41(11), 2684-2692
9. Neer CS (1983). Impingement lesions. *Clinical Orthopaedics and Related Research (1976-2007)*, 173, 70-77.
10. Cipollaro L (2019). Immunohistochemical features of rotator cuff tendinopathy. *British Medical Bulletin*, 130:105–123 doi: 10.1093/bmb/ldz016
11. Burkhart SS, Nottage WM, Ogilvie-Harris DJ, Kohn HS & Pachelli A (1994). Partial repair of irreparable rotator cuff tears. *Arthroscopy: The Journal of Arthroscopic & Related Surgery*, 10(4), 363-370.
12. Mesiha MM, Derwin KA, Sibole SC, Erdemir A, & McCarron JA (2013). The biomechanical relevance of anterior rotator cuff cable tears in a cadaveric shoulder model. *JBJS*, 95(20), 1817-1824.
13. Collin P, Matsumura N, Lädermann A, Denard PJ & Walch G (2014). Relationship between massive chronic rotator cuff tear pattern and loss of active shoulder range of motion. *Journal of shoulder and elbow surgery*, 23(8), 1195-1202.
14. MacDermid JC, Ghobrial M, Quirion KB, St-Amour M, Tsui T, Humphreys D ... & Galea V (2007). Validation of a new test that assesses functional performance of the upper extremity and neck (FIT-HaNSA) in patients with shoulder pathology. *BMC Musculoskeletal Disorders*, 8(1), 1-10.
15. Hamada K, Fukuda H, Mikasa M, Kobayashi Y (1990). Roentgenographic findings in massive rotator cuff tears: a long-term observation. *Clin Orthop Relat Res*, 254:92–96
16. Uzel AP, Bertino R & Boileau P (2011). Bilateral spontaneous tenodesis of the long head of the biceps at the bicipital groove with massive rotator cuff tear on a 103-year-old female cadaver: the natural evolution of the human shoulder?. *Musculoskeletal surgery*, 95(1), 79-82.
17. Sakurai G, Ozaki J, Tomita Y, Nakagawa Y, Kondo T & Tamai S (1998). Morphologic changes in long head of biceps brachii in rotator cuff dysfunction. *Journal of orthopaedic science*, 3(3), 137-142.4
18. Boileau P, Ahrens PM & Hatzidakis AM (2004). Entrapment of the long head of the biceps tendon: the hourglass biceps—a cause of pain and locking of the shoulder. *Journal of shoulder and elbow surgery*, 13(3), 249-257.
19. Walch G, Nové-Josserand L, Boileau P & Levigne C (1998). Subluxations and dislocations of the tendon of the long head of the biceps. *Journal of shoulder and elbow surgery*, 7(2), 100-108.

20. Lippman RK (1944). Bicipital tenosynovitis. *N Y State J M*, 1944:2235–41.
21. Beard DJ, Rees JL, Cook JA, Rombach I, Cooper C, Merritt N ... & Woods D (2018). Arthroscopic subacromial decompression for subacromial shoulder pain (CSAW): a multicentre, pragmatic, parallel group, placebo-controlled, three-group, randomised surgical trial. *The Lancet*, 391(10118), 329-338.
22. Papadonikolakis A, McKenna M, Warme W, Martin BI & Matsen III FA (2011). Published evidence relevant to the diagnosis of impingement syndrome of the shoulder. *JBSJ*, 93(19), 1827-1832.
23. Diercks R, Bron C, Dorrestijn O, Meskers C, Naber R, De Ruiter T ... & van der Woude HJ (2014). Guideline for diagnosis and treatment of subacromial pain syndrome: a multidisciplinary review by the Dutch Orthopaedic Association. *Acta orthopaedica*, 85(3), 314-322.
24. Lambers Heerspink FO, van Raay JJ, Koorevaar RC, van Eerden PJ, Westerbeek RE, van't Riet E ... & Diercks RL (2015). Comparing surgical repair with conservative treatment for degenerative rotator cuff tears: a randomized controlled trial. *Journal of shoulder and elbow surgery*, 24(8), 1274-1281.
25. Moosmayer S, Lund G, Seljom US, Haldorsen B, Svege IC, Hennig T ... & Smith HJ (2019). At a 10-Year Follow-up, Tendon Repair Is Superior to Physiotherapy in the Treatment of Small and Medium-Sized Rotator Cuff Tears. *J Bone Joint Surg Am. Jun 19*;101(12):1050-1060. doi: 10.2106/JBJS.18.01373. PMID: 31220021.
26. McElvany MD, McGoldrick E, Gee AO, Neradilek MB, & Matsen III FA (2015). Rotator cuff repair: published evidence on factors associated with repair integrity and clinical outcome. *The American journal of sports medicine*, 43(2), 491-500.
27. Randelli PS, Menon A, Nocerino E, Aliprandi A, Feroldi FM, Mazzoleni MG ... & Cucchi D (2019). Long-term results of arthroscopic rotator cuff repair: initial tear size matters: a prospective study on clinical and radiological results at a minimum follow-up of 10 years. *The American journal of sports medicine*, 47(11), 2659-2669.
28. Viswanath A & Monga P (2021). Trends in rotator cuff surgery: Research through the decades. *Journal of Clinical Orthopaedics and Trauma*, 18, 105-113.
29. Sochacki KR, Jack RA, Nauert R & Harris JD (2018). Correlation between quality of evidence and number of citations in top 50 cited articles in rotator cuff repair surgery. *Orthopaedic journal of sports medicine*, 6(6), 2325967118776635.
30. Jancuska J, Matthews J, Miller T, Kluczynski MA & Bisson LJ (2018). A systematic summary of systematic reviews on the topic of the rotator cuff. *Orthopaedic journal of sports medicine*, 6(9), 2325967118797891.
31. Ranalletta M (2017). CORR Insights®: What Influence Does Progression of a Nonhealing Rotator Cuff Tear Have on Shoulder Pain and Function?. *Clinical Orthopaedics and Related Research®*, 475(6), 1605-1607.
32. Meyer DC, Wieser K, Farshad M & Gerber C (2012). Retraction of supraspinatus muscle and tendon as predictors of success of rotator cuff repair. *The American journal of sports medicine*, 40(10), 2242-2247.
33. Lubiatuski P, Kaczmarek P, Dzianach M, Ogrodowicz P, Bręborowicz M, Długosz J ... & Romanowski L (2013). Clinical and biomechanical performance of patients with failed rotator cuff repair. *International orthopaedics*, 37(12), 2395-2401.
34. Hamada K, Yamanaka K, Uchiyama Y, Mikasa T & Mikasa M (2011). A radiographic classification of massive rotator cuff tear arthritis. *Clinical Orthopaedics and Related Research®*, 469(9), 2452-2460.
35. Brolin TJ, Updegrave GF & Horneff JG (2017). Classifications in brief: Hamada classification of massive rotator cuff tears. *Clinical Orthopaedics and Related Research®*, 475(11), 2819-2823.
36. Gilcreest EL (1936). Dislocation and elongation of the long head of the biceps brachii: an analysis of six cases. *Annals of Surgery*, 104(1), 118.
37. Kido T, Itoi E, Konno N, Sano A, Urayama M & Sato K (2000). The depressor function of biceps on the head of the humerus in shoulders with tears of the rotator cuff. *The Journal of bone and joint surgery. British volume*, 82(3), 416-419.



part one



**Ageing of the**  
**acromioclavicular joint**



**Predictive findings on  
magnetic resonance imaging  
in patients with symptomatic  
acromioclavicular osteoarthritis**

Egbert J.D. Veen  
Cornelia M. Donders  
Robin E. Westerbeek  
Rosalie P.H. Derks  
Ellie B.M. Landman  
Cornelis T. Koorevaar

*Journal of Shoulder and Elbow Surgery*  
2018, 27(8), e252-e258

## ABSTRACT

### Background

A magnetic resonance imaging (MRI) scan of the shoulder can have added value in diagnosing symptomatic osteoarthritis of the acromioclavicular (AC) joint. Specific MRI signs have been recognized but not analyzed extensively before. This study aims to identify predictive MRI signs in patients with symptomatic AC osteoarthritis.

### Methods

The MRI scans of 70 patients with symptomatic AC osteoarthritis were compared with those of 70 patients with subacromial pain syndrome and no clinical signs of symptomatic AC osteoarthritis. Seven variables were evaluated on the MRI scans of the AC joint: joint space narrowing, inferior osteophytes, joint effusion, osteolysis, bone marrow edema, impression on the supraspinatus, and inferior joint distension. Logistic regression analysis of these variables was performed.

### Results

The presence of inferior osteophytes, bone marrow edema, impression on the supraspinatus, and inferior joint distension was individually associated with symptomatic AC osteoarthritis. Bone marrow edema was observed only in patients with symptomatic AC osteoarthritis. Multivariate analysis showed a significant association between inferior joint distension, as well as impression on the supraspinatus muscle, and symptomatic AC osteoarthritis. The area under the receiver operating characteristic curve in the multivariate logistic model was 0.839 (95% confidence interval, 0.771 to 0.907). Interobserver and intraobserver variability showed good to excellent  $\kappa$  values (range, 0.68 to 0.88).

### Conclusion

We identified predictive MRI signs in patients with symptomatic AC osteoarthritis. These findings, including bone marrow edema, inferior joint distension, and impression on the supraspinatus muscle, showed good discriminative ability. They are practical and easy to use and can assist the physician in diagnosing symptomatic AC osteoarthritis.

### Level of evidence

Level IV; Case-Control Design; Diagnostic Study

### Keywords

AC joint; AC osteoarthritis; MRI scan; bone marrow edema; impression on musculus supraspinatus; predictive findings



## INTRODUCTION

Degeneration of the acromioclavicular (AC) joint, with joint space narrowing and osteophyte formation, is part of the normal ageing process.<sup>10,19</sup> In most of the general population, osteoarthritis of the AC joint is not symptomatic, but in some cases, such degenerative changes cause pain and loss of normal shoulder function.<sup>12</sup> Treatment of symptomatic osteoarthritis of the AC joint was proved effective with either injection therapy or distal clavicle resection.<sup>5,7,21</sup> However, the diagnostic accuracy of the patient's history and clinical examination findings is limited because of the complex anatomy and kinematics of the shoulder joint.<sup>4,16,17</sup>

The diagnosis of symptomatic AC osteoarthritis is made by an accurate history, clinical examination, and additional radiodiagnostic imaging studies. Previous studies have debated the accuracy and reliability of clinical tests of the AC joint.<sup>5,11</sup> Imaging techniques such as magnetic resonance imaging (MRI) scans could be of added value in patients with shoulder pain and could assist the clinician in determining treatment options.<sup>6,15</sup>

Previous research has shown that advanced signs of degeneration in the AC joint seen on the MRI scan are correlated with symptoms and that bone marrow edema is only observed in patients with symptomatic AC osteoarthritis.<sup>8,18</sup> Choo et al<sup>2</sup> observed that superior capsular distension of the AC joint on MRI scans was a predictable finding in symptomatic patients.

The aim of this study was to identify predictive MRI signs in patients with symptomatic AC osteoarthritis. We hypothesized that specific MRI signs would be found in patients with symptomatic AC osteoarthritis.

## Materials and methods

### Design

This study had a retrospective, case-control, diagnostic study design and was conducted in a general teaching hospital with a specialized shoulder unit.

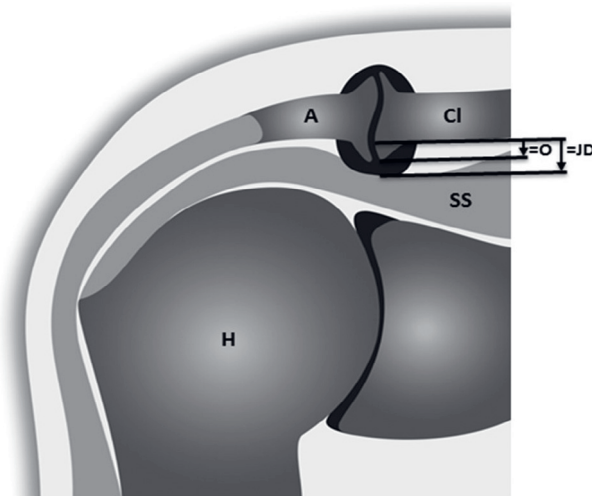
### Study population

A total of 140 patients were selected from the electronic patient files: 70 consecutive patients with clinical isolated symptomatic AC osteoarthritis (group 1) and 70 consecutive patients with chronic subacromial pain syndrome (group 2). Groups 1 and

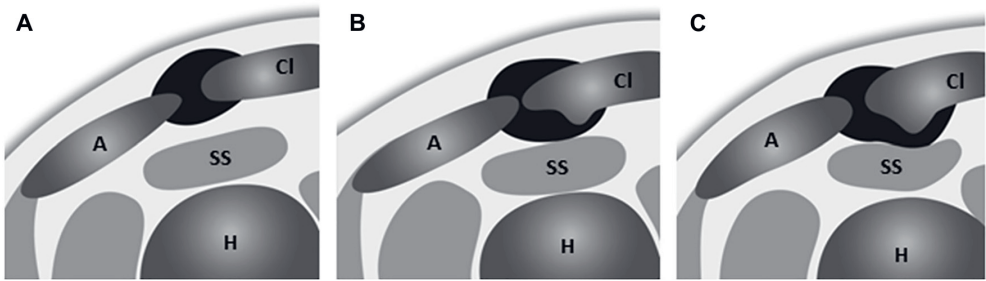
2 were matched for sex and age (maximal deviation of 5 years) to avoid bias resulting from age-related degeneration of the AC joint.<sup>18</sup>

Patients in both groups were recruited from our outpatient department: group 1 in 2009 to 2014 and group 2 in 2012 to 2014. The inclusion criteria for group 1 were pain localized in the AC joint that increased with activities requiring cross-body adduction, focal tenderness at the AC joint, and a positive cross-body adduction test. Patients with additional shoulder disorders, as stated later, were excluded in order to include only patients with clinical isolated symptomatic AC osteoarthritis. Group 2 consisted of patients with nontraumatic shoulder problems that caused pain localized around the acromion, which worsened during lifting of the arm; a positive Hawkins test; a positive empty-can test; and/or focal tenderness of the supraspinatus. The exclusion criteria for group 2 were focal tenderness of the AC joint and a positive cross-body adduction test. The exclusion criteria for both groups were rheumatoid arthritis, a history of shoulder surgery or fracture, glenohumeral osteoarthritis, ruptures of the cuff or labrum on MRI scans, or clinical painful biceps tendinopathy.

All patients with shoulder pain were reviewed in our shoulder unit by 2 experienced shoulder surgeons using a standard protocol for clinical history and clinical examination. Data were collected in a standardized manner and noted in patients' electronic medical files. The following clinical variables were assessed and stored in a database: age, sex, affected side, dominant side, duration of shoulder complaints, focal tenderness at the AC joint, cross-body adduction test, Hawkins test, empty-can test, and focal tenderness of the supraspinatus.



**Figure 1.** Measurement of inferior osteophyte (*O*) and inferior joint distension (*JD*) on coronal image from magnetic resonance imaging scan. *A*, acromion; *Cl*, clavicle; *SS*, supraspinatus; *H*, humerus.



**Figure 2.** Compression of supraspinatus on sagittal images from magnetic resonance imaging scans: no contact (**A**), adjacent (**B**), and impression (**C**). *A*, acromion; *Cl*, clavicle; *SS*, supraspinatus; *H*, humerus.

### Signs on MRI

All MRI scans were performed 2 to 3 weeks after the outpatient visit in our hospital on a 1.5-T Signa HDx TwinSpeed1 MRI system (General Electric, Milwaukee, WI, USA). The shoulder was placed in a dedicated shoulder coil while in external rotation. All MRI scans were performed according to a standard protocol. Coronal T2-weighted fat-saturated images, sagittal T1-weighted or proton density sequences, and axial images were obtained for each patient. All MRI scans were evaluated blindly on a consensus basis by a musculoskeletal radiologist, an orthopedic surgeon, and a final-year medical student.

On the basis of previous research and clinical experience, 7 variables were evaluated on the MRI scans:

1. AC joint space narrowing: minimal space between the clavicle and acromion on axial images, with the cutoff value for joint space narrowing set at 2 mm
2. AC joint effusion: fluid-equivalent signal in the AC joint space
3. Subchondral bone marrow edema of the distal clavicle and/ or medial acromion: hyperintense signal from cranial to caudal on fat-saturated T2-weighted images and hypointense signal on T1-weighted images
4. AC osteolysis: lytic bone lesion with cortical destruction of the distal clavicle
5. AC inferior osteophytes: inferior osteophyte, 2 mm or longer (length measured from a horizontal line on the original undersurface of the clavicle on coronal images, Fig. 1).
6. Inferior AC joint distension: distal protrusion of the AC joint, 3 mm or longer (measured from a horizontal line on the original undersurface of the clavicle on sagittal or coronal images, Fig. 1).
7. Impression on the supraspinatus due to the AC joint: 3 scores (on sagittal T1 or proton density sequences): (1) normal fat between AC joint and supraspinatus, (2) no fat between AC joint and supraspinatus, and (3) an indentation on the supraspinatus (Fig. 2)

To enhance interpretation of the findings on MRI in clinical practice, variables were expressed dichotomously. Cutoff values for joint space narrowing, inferior osteophytes, and joint distension were based on the 75th percentile and rounded to the nearest millimeter.

## STATISTICAL ANALYSIS

### Demographic and clinical characteristics

The demographic and clinical characteristics were presented as proportion, mean (standard deviation), or median (interquartile range) in the case of a skewed distribution. Differences between patients with symptomatic AC osteoarthritis and the control group were tested using independent-samples *t* tests for continuous variables or  $\chi^2$  tests for categorical variables.

### Analysis of MRI predictors for symptomatic AC osteoarthritis

Univariate logistic regression analyses were performed to evaluate the association between each of the MRI findings individually and symptomatic AC osteoarthritis. MRI findings showing a significant association with symptomatic AC osteoarthritis in the univariate analysis were included in a multivariate logistic regression analysis with the presence or absence of symptomatic AC osteoarthritis as the dependent variable. Sample size calculation was based on the recommendations of Peduzzi et al<sup>14</sup> to include 10 patients for each predictor. With 7 MRI signs, we included 70 patients in the symptomatic AC osteoarthritis group and 70 patients in the control group. A manual backward selection strategy of variables with  $P > .10$  was performed to select predictors for the final model. Predictors were deleted step by step from the model based on the highest  $P$  value. Next, goodness of fit was evaluated using the Hosmer-Lemeshow test, and prediction scores were calculated using the following formula:  $P = \exp[\ln(\text{odds})]/(1 + \exp[\ln(\text{odds})])$ . Calculated predictions were used to evaluate the discriminative power of the model, expressed by the area under the receiver operating characteristic (ROC) curve. SPSS statistical software (version 20.0; IBM, Armonk, NY, USA) was used for data compilation and statistical analyses.

### Intraobserver and interobserver variability

Intraobserver and interobserver variability was calculated for the findings of the final multivariate logistic regression model. This was done by calculating the  $\kappa$  value, using data from 20 patients from the symptomatic AC group and 20 from the subacromial pain group. The patients were chosen at random by SPSS and mixed blindly. The MRI findings were scored by a panel of judges consisting of a musculoskeletal radiologist (R.E.W.), a radiology medical resident (R.P.H.D.), and a final-year medical student (C.M.D.). Interobserver variability was evaluated by comparing the values within the panel of

judges; intraobserver variability was evaluated by scoring the variables twice by the panel of judges on 2 days in different weeks at random. A  $\kappa$  value between 0.61 and 0.80 is considered substantial agreement, and a  $\kappa$  value between 0.81 and 1.00 is considered almost perfect agreement.<sup>9</sup>

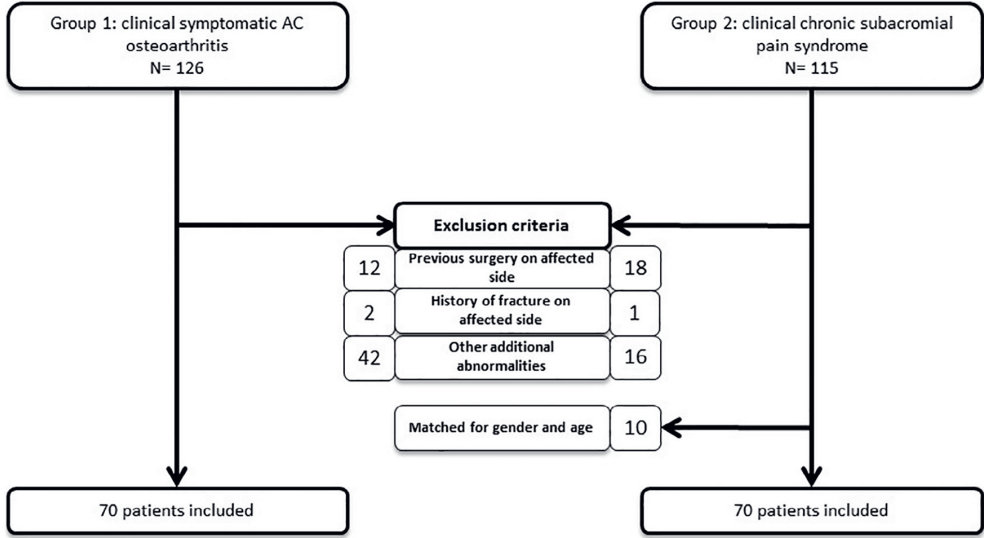


Figure 3. Flowchart of study enrollment. AC, acromioclavicular.

## RESULTS

### Demographic characteristics

Figure 3 shows a flow diagram of study enrollment. Between 2009 and 2014, 126 consecutive patients presented with clinical symptoms of AC osteoarthritis. To include only patients with isolated symptomatic AC osteoarthritis, 42 patients were excluded with additional shoulder pathology (ruptures of the rotator cuff or labrum, glenohumeral osteoarthritis, and biceps tendinopathy). Patients were also excluded because of a history of shoulder surgery ( $n = 12$ ) or fracture ( $n = 2$ ) on the affected side. Between 2012 and 2014, 115 consecutive patients presented with clinical chronic subacromial pain syndrome; we excluded 18 of them because of a history of shoulder operations on the affected side, 1 with a history of fracture on the affected side, and 16 because of other shoulder pathology (ruptures of the rotator cuff or labrum, glenohumeral osteoarthritis, and biceps tendinopathy). No patients were excluded because of incomplete data. To match both groups for sex and age, 10 more patients were removed from group 2. As such, group 1 consisted of 70 patients with clinical symptoms of AC osteoarthritis, and group 2 consisted of 70 patients with clinical chronic subacromial pain syndrome.

Complete demographic and clinical data for both groups are shown in Table I. Demographic parameters were comparable between the 2 groups. Significant differences were found between groups in the size of inferior AC osteophytes ( $P = .011$ ) and inferior AC joint distension ( $P < .001$ ). Bone marrow edema was observed only in patients with AC osteoarthritis. Osteolysis was not found in any of the patients.

**Table I.** Demographic and clinical data and MRI findings of study population

	Group 1 (n = 70)	Group 2 (n = 70)	P value
Male sex	32 (45.7%)	34 (48.6%)	.735
Mean age (SD), yr	49.7 (9.7)	52.6 (8.8)	.071
Symptoms on right side	47 (67.1%)	40 (57.1%)	.223
Dominant hand affected	47 (67.1%)	37 (52.9%)	.084
Duration of pain until first visit, mean (SD), mo	20 (23)	19 (25)	.075
Focal tenderness at AC joint	70 (100.0%)	0 (0.0%)	<.001
Positive cross-body adduction test	70 (100.0%)	0 (0.0%)	<.001
Positive Hawkins test	56 (83.6%)*	56 (80%)	.587
Focal tenderness of supraspinatus	28 (40.6%)†	27 (38.6%)	.809
Positive empty-can test	35 (52.2%)*	49 (70.0%)	.038
MRI findings of AC joint, mean (SD), mm			
Joint width	0.96 (1.2)	0.86 (1.1)	.584
Inferior osteophyte	0.55 (0.9)	1.10 (1.5)	.011
Inferior joint distension	2.97 (1.5)	1.02 (1.2)	<.001

MRI, magnetic resonance imaging; SD, standard deviation; AC, acromioclavicular.

Group 1 patients had symptomatic AC osteoarthritis, and group 2 patients had chronic subacromial pain syndrome.

\* Data are missing for 3 patients.

† Data are missing for 1 patient.

**Table II.** Univariate association between potential predictor variables on MRI and symptomatic AC osteoarthritis

	Group 1 (n = 70)	Group 2 (n = 70)	Odds ratio (95% CI)	P value
Joint space $\leq 2$ mm	57 (81%)	71 (87%)	0.647 (0.257-1.629)	.355
Inferior osteophyte $\geq 2$ mm	20 (29%)	8 (11%)	3.100 (1.260-7.629)	.014
Inferior joint distension $\geq 3$ mm	35 (50%)	8 (11%)	7.750 (3.238-18.549)	<.001
Impression on supraspinatus	37 (53%)	4 (6%)	18.50 (6.08-56.31)	<.001
Joint effusion	20 (29%)	14 (20%)	1.60 (0.73-3.50)	.239
Bone marrow edema	30 (43%)	0 (0%)	—	—
Osteolysis	0 (0%)	0 (0%)	—	—

MRI, magnetic resonance imaging; AC, acromioclavicular; CI, confidence interval.

Group 1 patients had symptomatic AC osteoarthritis, and group 2 patients had chronic subacromial pain syndrome.

**Table III** Multivariate logistic regression analysis of predictors on MRI for symptomatic AC osteoarthritis

Variable	Coefficient	Odds ratio (95% CI)	P value
Inferior joint distension $\geq 3$ mm	1.217	3.378 (1.249-9.133)	.016
Impression on supraspinatus	2.428	11.340 (3.529-36.441)	<.001

MRI, magnetic resonance imaging; AC, acromioclavicular; CI, confidence interval.

### MRI characteristics

Because bone marrow edema was found only in patients with symptomatic AC osteoarthritis and because osteolysis was not found in any patients, these variables were not included in the regression analyses. Hence, 5 potential predictor variables of the AC joint—joint space narrowing, inferior osteophytes, inferior joint distension, impression on the supraspinatus, and joint effusion—were considered for inclusion in the model. In the univariate logistic regression analysis, joint space narrowing and joint effusion showed no significant relation with symptomatic AC osteoarthritis (Table II) and were not included in the multivariate logistic regression model. The variable of inferior osteophytes did not contribute significantly to the multivariate model and was subsequently removed. The final model (Table III) included impression on the supraspinatus (odds ratio, 11.34; 95% confidence interval [CI], 3.53 to 36.44;  $P < .001$ ) and joint distension (odds ratio, 3.38; 95% CI, 1.25 to 9.13;  $P = .016$ ).

The Hosmer-Lemeshow test for goodness of fit of the model including these 2 variables was performed including only those patients without bone marrow edema and was not significant ( $P = .963$ ), indicating no evidence for failure of model fit. An ROC curve was generated to evaluate the discriminative ability of the model, with bone marrow edema added to the prediction line. The area under the ROC curve of the model was 0.839 (95% CI, 0.771 to 0.907), indicating that the model had good discriminative power.

### Intraobserver and interobserver variability

The mean  $\kappa$  value for intraobserver variability was 0.86 (95% CI, 0.75 to 1.00) for bone marrow edema, 0.68 (95% CI, 0.60 to 0.795) for AC joint distension, and 0.85 (95% CI, 0.75 to 0.94) for impression. The mean  $\kappa$  value for interobserver variability was 0.88 (95% CI, 0.82 to 0.94) for bone marrow edema, 0.70 (95% CI, 0.65 to 0.75) for AC joint distension, and 0.84 (95% CI, 0.82 to 0.94) for impression. The mean intraobserver variability and interobserver variability of impression and bone marrow edema were excellent, showing almost perfect agreement, with mean  $\kappa$  values above 0.81.<sup>9</sup> For impression, intraobserver variability and interobserver variability were considered to show substantial agreement, with  $\kappa$  values of 0.68 and 0.70, respectively.

## DISCUSSION

The most important finding of our study was the correlation of 3 MRI signs with the clinical diagnosis of symptomatic AC osteoarthritis. The presence of bone marrow edema predicted a 100% probability for clinical symptomatic AC osteoarthritis. If no bone marrow edema was found, the presence of AC joint distension and/or impression on the supraspinatus muscle predicted clinical symptomatic AC osteoarthritis with good discriminative power. These predictive findings, with good to excellent  $\kappa$  values, are easy to use and can assist the physician in diagnosing symptomatic AC osteoarthritis and exclude other shoulder pathology.

Several clinical tests are available to diagnose symptomatic AC osteoarthritis. Painful palpation of the AC joint has a sensitivity of 96% and specificity of 10%.<sup>22</sup> Cross-body adduction has a sensitivity of 77% and specificity of 79%.<sup>3</sup> We used a combination of these 2 tests as inclusion criteria in this study because they are the most frequently used in clinical practice for diagnosing AC joint pathology. The sensitivity and specificity of these 2 clinical tests combined are, to our knowledge, unknown. Other clinical tests are the O'Brien test, the Paxinos test, and the AC resisted extension test, with varying accuracy.<sup>3,13,22</sup> The current diagnostic process in shoulder pathology includes a clinical history, physical examination with clinical tests, and additional radiographic examinations. The presented predictive signs on MRI scans in this study can facilitate the diagnostic process. The finding of bone marrow edema, AC joint distension, and/or impression on the supraspinatus muscle indicates that the patient has a high probability of having symptomatic AC osteoarthritis.

There are limited data available in the literature about the association between abnormal findings around the AC joint on an MRI scan and clinical tests of patients with symptoms of a degenerative AC joint.<sup>2,8,18</sup> In our study, bone marrow edema in the clavicle or acromion was only observed in patients with symptomatic AC osteoarthritis and not in the control group. This was also found by Jordan et al<sup>8</sup> and Stein et al,<sup>18</sup> who noted a statistically significant correlation between high signal in the distal clavicle and clinical tests for AC osteoarthritis.

Another study showed the association of osteophytes and AC joint distension with symptomatic AC osteoarthritis,<sup>2</sup> and its findings were confirmed in our study. Strobel et al<sup>20</sup> retrospectively evaluated the association of deviations of a degenerative AC joint on an MRI scan with pain relief after intra-articular steroid injection (fluoroscopically controlled). They found a significant correlation between capsular distension of 3 mm or greater and pain relief after injection. The use of an intra-articular injection into the AC joint to indicate whether a degenerative AC joint is symptomatic is under debate. In our



opinion, ultrasound-guided intra-articular injections into the AC joint do not indicate whether AC osteoarthritis is symptomatic. We observed that the protrusion of the AC joint into the subacromial space probably also causes pain. As a result, the symptoms caused by the protrusion are not likely to respond to intra-articular injections into the AC joint. Inferior osteophytes were defined in our study as 2 mm or greater based on the 75th percentile, and other studies showed that inferior osteophytes ( $\geq 2$  mm) were highly associated with rotator cuff tendon disruption.<sup>14,18</sup>

The comparative study of Choo et al<sup>2</sup> found bone edema in only 9% of symptomatic patients. This finding is in contrast to our study but may be the result of using another fat-saturated MRI protocol (T2-weighted images). In our study we measured inferior joint distension by combining the length of the osteophyte with the thickness of the capsular wall. We hypothesized that this inferior joint distension is clinically more relevant and will give a more realistic impression of the protrusion of the AC joint into the subacromial space. In 50% of our patients with symptomatic AC osteoarthritis, inferior joint distension was 3 mm or greater.

One of the strengths of this study is the relatively large group of consecutive patients with isolated symptomatic AC osteoarthritis and the comparison with a control group of patients with subacromial pain syndrome, matched for sex and age. We evaluated 7 variables on MRI scans; 6 of them had been evaluated in previous studies.

This study also has some limitations. It has a retrospective design, creating a risk of selection bias. Our control group (group 2) consisted of patients with shoulder pain caused by subacromial pain syndrome without clinical signs of osteoarthritis of the AC joint. In future studies we suggest using a control group of volunteers with no pain in the shoulder undergoing clinical shoulder tests and an MRI scan. We aimed to study only patients with clinical isolated symptomatic AC osteoarthritis and therefore had to exclude many patients with symptomatic AC osteoarthritis but also additional shoulder pathology. Other studies also observed that in many patients, other shoulder pathology coexists with a degenerative AC joint.<sup>1,10</sup> Another limitation was that the inclusion criteria were based on clinical signs. The diagnosis of symptomatic AC osteoarthritis is made by an accurate history, clinical examination, and additional radio-diagnostic imaging studies. Painful palpation of the AC joint and a positive cross-body adduction test were used as clinical tests for inclusion. The sensitivity and specificity of these 2 tests combined are unknown. We recognize that, by using these clinical tests as inclusion criteria, patients may have been incorrectly allocated to either group. This may have an effect on the accuracy of the outcomes of this study. Ultrasound-guided intraarticular injections into the AC joint are, in our opinion, not the gold standard to identify or exclude symptomatic AC osteoarthritis. Further studies should indicate whether a

combination of ultrasound-guided injections into the AC joint and into the subacromial space could be used to confirm that symptoms are caused by AC joint osteoarthritis.

The prediction of symptomatic AC osteoarthritis using impression on the supraspinatus, joint distension, and bone marrow edema is based on point estimates of the coordinates for each of the variables, with wide CIs, which might indicate that adequate power is lacking in this study. Bootstrapping of these CIs could give a more approximate estimation. The reliability of these predictive signs on MRI should be confirmed in prospective, adequately powered studies. Consequent prospective studies could also include outcomes of subsequent treatment to confirm whether the correct diagnosis was made.

## CONCLUSION

In this study we identified predictive MRI signs in patients with symptomatic AC osteoarthritis. A prediction model, including bone marrow edema, inferior joint distension, and impression on the supraspinatus muscle, showed good discriminative ability. These predictive findings are practical, are easy to use, and can assist the physician in diagnosing symptomatic AC osteoarthritis.

### Disclaimer

The authors, their immediate families, and any research foundations with which they are affiliated have not received any financial payments or other benefits from any commercial entity related to the subject of this article.

## REFERENCES


1. Brown JN, Roberts SN, Hayes MG, Sales AD. Shoulder pathology associated with symptomatic acromioclavicular joint degeneration. *J Shoulder Elbow Surg* 2000;9:173-6.
2. Choo HJ, Lee SJ, Kim JH, Cha SS, Park YM, Park JS, et al. Can symptomatic acromioclavicular joints be differentiated from asymptomatic acromioclavicular joints on 3-T MR imaging? *Eur J Radiol* 2013;82:e191. <http://dx.doi.org/10.1016/j.ejrad.2012.10.027>
3. Chronopoulos E, Kim TK, Park HB, Ashenbrenner D, McFarland EG. Diagnostic value of physical tests for isolated chronic acromioclavicular lesions. *Am J Sports Med* 2004;32:655-61. <http://dx.doi.org/10.1177/0363546503261723>
4. Colegate-Stone T, Allom R, Singh R, Elias DA, Standing S, Sinha J. Classification of the morphology of the acromioclavicular joint using cadaveric and radiological analysis. *Bone Joint J* 2010;92:743-6. <http://dx.doi.org/10.1302/0301-620X.92B5.22876>
5. Docimo S Jr, Kornitsky D, Futterman B, Elkowitz DE. Surgical treatment for acromioclavicular joint osteoarthritis: patient selection, surgical options, complications, and outcome. *Curr Rev Musculoskelet Med* 2008;1:154-60. <http://dx.doi.org/10.1007/s12178-008-9024-5>
6. Heers G, Götz J, Schachner H, Neumaier U, Grifka J, Hedtmann A. Ultrasound evaluation of the acromioclavicular joint. A comparison with magnetic resonance imaging. *Sportverletz Sportschaden* 2005;19:177-81 [in German]. <http://dx.doi.org/10.1055/s-2005-858871>
7. Hossain S, Jacobs LG, Hashmi R. The long-term effectiveness of steroid injections in primary acromioclavicular joint arthritis: a five-year prospective study. *J Shoulder Elbow Surg* 2008;17:535-8. <http://dx.doi.org/10.1016/j.jse.2007.12.001>
8. Jordan L, Kenter K, Griffiths H. Relationship between MRI and clinical findings in the acromioclavicular joint. *Skeletal Radiol* 2002;31:516-21. <http://dx.doi.org/10.1007/s00256-002-0530-z>
9. Landis JR, Koch GG. The measurement of observer agreement for categorical data. *Biometrics* 1977;159-74.
10. Mall NA, Foley E, Chalmers PN, Cole BJ, Romeo AA, Bach BR Jr. Degenerative joint disease of the acromioclavicular joint: a review. *Am J Sports Med* 2013;41:2684-92. <http://dx.doi.org/10.1177/0363546513485359>
11. McFarland EG, Garzon-Muvdi J, Jia X, Desai P, Petersen SA. Clinical and diagnostic tests for shoulder disorders: a critical review. *Br J Sports Med* 2010;44:328-32. <http://dx.doi.org/10.1136/bjsm.2009>
12. Menge TJ, Boykin RE, Bushnell BD, Byram IR. Acromioclavicular osteoarthritis: a common cause of shoulder pain. *South Med J* 2014;107:324-9. <http://dx.doi.org/10.1097/SMJ.0000000000000101>
13. O'Brien SJ, Pagnani MJ, Fealy S, McGlynn SR, Wilson JB. The active compression test: a new and effective test for diagnosing labral tears and acromioclavicular joint abnormality. *Am J Sports Med* 1998;26: 610-3.
14. Peduzzi P, Concato J, Kemper E, Holford TR, Feinstein AR. A simulation study of the number of events per variable in logistic regression analysis. *J Clin Epidemiol* 1996;49:1373-9.
15. Pensak M, Grumet RC, Slabaugh MA, Bach BR. Open versus arthroscopic distal clavicle resection. *Arthroscopy* 2010;26:697-704. <http://dx.doi.org/10.1016/j.arthro.2009.12.007>
16. Raynor MB, Kuhn JE. Utility of features of the patient's history in the diagnosis of atraumatic shoulder pain: a systematic review. *J Shoulder Elbow Surg* 2016;25:688-94. <http://dx.doi.org/10.1016/j.jse.2015.09.023>
17. Schünke M, Schulte E, Schumacher U, Voll M, Wesker K. Anatomische atlas Prometheurs: algemene anatomie en bewegingsapparaat. Stuttgart, Germany: Thieme; 2005.
18. Shubin Stein BE, Ahmad CS, Pfaff CH, Bigliani LU, Levine WN. A comparison of magnetic resonance imaging findings of the acromioclavicular joint in symptomatic versus asymptomatic patients. *J Shoulder Elbow Surg* 2006;15:56-9. <http://dx.doi.org/10.1016/j.jse.2005.05.013>

19. Shubin Stein BE, Wiater JM, Pfaff HC, Bigliani LU, Levine WN. Detection of acromioclavicular joint pathology in asymptomatic shoulders with magnetic resonance imaging. *J Shoulder Elbow Surg* 2001;10:204-8.
20. Strobel K, Pfirrmann CW, Zanetti M, Nagy L, Hodler J. MRI features of the acromioclavicular joint that predict pain relief from intraarticular injection. *AJR Am J Roentgenol* 2003;181:755-60. <http://dx.doi.org/10.2214/ajr.181.3.1810755>
21. van Riet RP, Goehre T, Bell SN. The long term effect of an intra-articular injection of corticosteroids in the acromioclavicular joint. *J Shoulder Elbow Surg* 2012;21:376-9. <http://dx.doi.org/10.1016/j.jse.2011.05.010>
22. Walton J, Mahajan S, Paxinos A, Marshall J, Bryant C, Shnier R, et al. Diagnostic values of tests for acromioclavicular joint pain. *J Bone Joint Surg Am* 2004;86:807-12.





part two



**Ageing of the  
rotator cuff: functional  
analysis of patients with  
degenerative rotator cuff  
tears, and surgery of the long  
head of biceps tendon**





**Compensatory movement  
patterns are based on abnormal  
activity of the biceps brachii  
and posterior deltoid muscles  
in patients with symptomatic  
rotator cuff tears**

Egbert J.D. Veen  
Cornelis T. Koorevaar  
Koen H.M. Verdonschot  
Tim E. Sluijter  
Tom de Groot  
Johannes H. van der Hoeven  
Ronald L. Diercks  
Martin Stevens

## ABSTRACT

### Background

Abnormal movement patterns due to compensatory mechanisms have been reported in patients with rotator cuff tears. The long head of the biceps tendon may especially be overactive and a source of pain and could induce abnormal muscle activation in these patients. It is still unknown why some patients with a rotator cuff tear develop complaints and others do not.

### Questions/purposes

(1) Which shoulder muscles show a different activation pattern on electromyography (EMG) while performing the Functional Impairment Test-Hand and Neck/Shoulder/Arm (FIT-HaNSA) in patients with a symptomatic rotator cuff tear compared with age-matched controls with an intact rotator cuff? (2) Which shoulder muscles are coactivated on EMG while performing the FIT-HaNSA?

### Methods

This comparative study included two groups of people aged 50 years and older: a group of patients with chronic symptomatic rotator cuff tears (confirmed by MRI or ultrasound with the exclusion of Patte stage 3 and massive rotator cuff tears) and a control group of volunteers without shoulder conditions. Starting January 2019, 12 patients with a chronic rotator cuff tear were consecutively recruited at the outpatient orthopaedic clinic. Eleven age-matched controls (randomly recruited by posters in the hospital) were included after assuring the absence of shoulder complaints and an intact rotator cuff on ultrasound imaging. The upper limb was examined using the FIT-HaNSA (score: 0 [worst] to 300 seconds [best]), shoulder-specific instruments, health-related quality of life, and EMG recordings of 10 shoulder girdle muscles while performing a tailored FIT-HaNSA.

### Results

EMG (normalized root mean square amplitudes) revealed hyperactivity of the posterior deltoid and biceps brachii muscles during the upward phase in patients with rotator cuff tears compared with controls (posterior deltoid: 111%  $\pm$  6% versus 102%  $\pm$  10%, mean difference -9 [95% confidence interval -17 to -1];  $p = 0.03$ ; biceps brachii: 118%  $\pm$  7% versus 111%  $\pm$  6%, mean difference -7 [95% CI -13 to 0];  $p = 0.04$ ), and there was decreased activity during the downward phase in patients with rotator cuff tears compared with controls (posterior deltoid: 89%  $\pm$  6% versus 98%  $\pm$  10%, mean difference 9 [95% CI 1 to 17];  $p = 0.03$ ; biceps brachii: 82%  $\pm$  7% versus 89%  $\pm$  6%, mean difference 7 [95% CI 0 to 14];  $p = 0.03$ ). The posterior deltoid functioned less in conjunction with the other deltoid muscles, and lower coactivation was seen in the remaining intact rotator cuff muscles in the rotator cuff tear group than in the control group.

### **Conclusion**

Patients with a symptomatic rotator cuff tear show compensatory movement patterns based on abnormal activity of the biceps brachii and posterior deltoid muscles when compared with age-matched controls. The posterior deltoid functions less in conjunction with the other deltoid muscles, and lower coactivation was seen in the remaining intact rotator cuff muscles in the rotator cuff tear group than the control group.

### **Clinical Relevance**

This study supports the potential benefit of addressing the long head biceps tendon in the treatment of patients with a symptomatic rotator cuff tear. Moreover, clinicians might use these findings for conservative treatment; the posterior deltoid can be specifically trained to help compensate for the deficient rotator cuff.

## INTRODUCTION

Degeneration of the rotator cuff tendon might lead to the development of rotator cuff tears, which can result in pain and limited function [10]. Some patients have severe and lasting functional limitations, while others experience only a small period of discomfort and milder symptoms by adapting to shoulder function limitation. There are indications that the long head of the biceps tendon plays an important role in patients with rotator cuff tears because it is the one remaining structure preventing the humeral head from migrating [18, 29]. The cross-sectional area of the tendon is often enlarged in patients with a massive rotator cuff tear (MRCT), defined as more than two tendons involved and/or more than 5-cm retraction, which adds to the idea that the long head of the biceps tendon adapts its function [30]. A previous electromyography (EMG) study showed that the biceps tendon is activated in patients with a rotator cuff tear, although that study was conducted in individuals with rotator cuff tears of different sizes and the control group consisted of young people with no shoulder symptoms [9, 13, 14]. In one of these studies, increased activity of the middle and posterior deltoid was seen in patients with an MRCT [9]. It is thought that it serves as compensation for the loss of abduction torque of the supraspinatus.

In patients with resolving pain after a rotator cuff tear, a change in the activation and collaboration of the surrounding shoulder muscles to compensate for the insufficient rotator cuff is proposed [24, 12]. Cadaveric studies mention increased strain on the deltoid muscle [6]. The mechanism of this is not well understood [20]. Also, the exact role of the long head of the biceps tendon is not clarified—whether it buckles and impinges [2] or serves as a depressor and becomes overloaded and painful [4, 14]. The activity of the shoulder girdle muscles has been studied before with EMG [8, 9, 13, 26, 27], but evidence of differences between patients with a symptomatic rotator cuff tear and controls remains limited [27]. Case-control studies on this topic have been conducted, but with young healthy controls instead of same-age peers of patients with degenerative changes in the shoulder [9, 16]. Additional flaws noted in other studies were the lack of sample size, different rotator cuff tear sizes, tests not resembling daily activities [9, 27], and failure to accommodate age- and sex-related nerve changes [5, 19].

We therefore asked: (1) Which shoulder muscles show a different activation pattern on EMG while performing the Functional Impairment Test-Hand and Neck/Shoulder/Arm (FIT-HaNSA) in patients with a symptomatic rotator cuff tear compared with age-matched controls with an intact rotator cuff tear? (2) Which shoulder muscles are coactivated on EMG while performing the FIT-HaNSA?

## PATIENTS AND METHODS

### Design

This was a comparative study conducted between January 2019 and August 2019. Our study compared a group of patients aged 50 years or older who had chronic symptomatic rotator cuff tears and an age-matched control group of volunteers without shoulder conditions. We obtained written informed consent from all participants, and the study was approved by the institutional review board of the University Medical Center Groningen (UMCG) (no. 2018/617) and registered in the Dutch Registry on research involving humans (no. NL68208.042.18). The study was conducted according to the principles of the Declaration of Helsinki and in conformity with the Medical Research Involving Human Subjects Act and other guidelines, regulations, and laws. The study met the Good Clinical Practice standard, and the Strengthening the Reporting of Observational Studies in Epidemiology guidelines were followed [32].

### Participants

#### *Rotator Cuff Tear Group*

Patients with symptomatic, chronic degenerative rotator cuff tears (confirmed by MRI or ultrasound by an experienced musculoskeletal radiologist) were consecutively recruited at the outpatient clinic at the Orthopaedic Department of University Medical Center Groningen (UMCG). The rotator cuff tear group had been treated nonoperatively with subacromial injections for at least 3 months and physiotherapy using a standard protocol. In addition to explaining the cause of the symptoms and the rehabilitation protocol, the physiotherapist advised about activities of daily living. Passive glenohumeral and scapulothoracic movements were performed, and static and dynamic exercises were started. The aim of these exercises was to improve the glenohumeral and scapulothoracic musculature. Poor posture was corrected. In weeks 4 to 6, exercises were gradually increased, and deltoid training was started. In weeks 6 to 12, rehabilitation was aimed at further optimization of mobility and strength regeneration of the remaining cuff and deltoid muscles. Physiotherapy was continued until patients reached an optimum ROM and improved strength was achieved. If complaints persisted, patients were referred by their general practitioner to the outpatient orthopaedic clinic. We excluded participants younger than 50 years and those with symptomatic glenohumeral or acromioclavicular osteoarthritis based on examination and radiographs, Patte Stage 3 tears, MRCTs, a positive Hornblower test [7], previous surgery of the same shoulder, neurological deficits afflicting the arm, other diseases causing shoulder impairment, rheumatoid arthritis, and cervical spine conditions.

Starting in January 2019, 16 patients with a chronic rotator cuff tear were consecutively identified at the outpatient clinic. The following patients were excluded: one patient had a history of previous ipsilateral proximal humeral fracture, one had a congenital collagen disease, and another one had an MRCT. In total, 13 eligible candidates were recruited, and after one patient withdrew after reading the information brochure, 12 participants remained. All patients in the rotator cuff tear group had a tear of the supraspinatus tendon, Stage 1 or 2 according to the Patte classification. Additional small partial tears and one full tear of the subscapularis tendon and infraspinatus tendon were seen with inevitable subluxation of the biceps tendon.

### *Control Group*

A total of 11 controls volunteered by responding to posters and flyers hanging at several public areas throughout UMCG; they were matched by age to patients in the rotator cuff tear group and consecutively included. Exclusion criteria were any previous surgery of the same shoulder, neurological deficits affecting the arm, other diseases causing shoulder impairment, rheumatoid arthritis, and cervical spine conditions. Before this visit, control participants with no shoulder symptoms in their dominant arm were examined with ultrasound by an experienced musculoskeletal radiologist at our institution to rule out asymptomatic rotator cuff tears or other shoulder abnormalities.

After providing written informed consent, all participants made an appointment at the clinical neurophysiology laboratory of UMCG to undergo tests, complete questionnaires, and undergo a physical examination by an unblinded research team (including the first author [EJDV] on every examination).

### **Functional Assessment: FIT-HaNSA and Questionnaires**

The functional status of the upper limb was assessed using the Functional Impairment Test-Hand and Neck/Shoulder/Arm (FIT-HaNSA) (score: 0 [worst] to 300 seconds [best] function). The test is based on activities of daily living and is extensively used in upper limb research. It is considered a reliable and valid test for assessing patients with shoulder conditions [8, 9, 15, 17]. As detailed by MacDermid et al. [17], the test consists of three subtasks. Task 1 involves consecutively lifting three 1-kg weights between two shelves, one positioned at the level of the participant's anterior superior iliac spine and a second 25 cm above. Task 2 differs in that one shelf is positioned at eye level and the second is 25 cm below. Task 3 involves screwing and unscrewing bolts on a plate positioned overhead. Participants are required to perform each task either for 300 seconds or until one of the criteria for stopping is met (pain or inability to proceed because of weakness).

A physical examination was additionally conducted, which included the Constant Murley score (CMS), a shoulder-specific score that ranges from 0 to 100 points if there are no

complaints and/or deficits (minimum clinically important difference [MCID] 10.4 points), and the Hornblower test for the teres minor muscle [7]. Additional questionnaires were VAS-pain (0 to 100 points for the most shoulder pain) and the Western Ontario Rotator Cuff (WORC) Index [33], which is a disease-specific quality-of-life measurement tool for patients with rotator cuff disease (0 to 2100 points if there are no complaints [MCID -282.6 points]); and the EuroQol-5D, which is a generic health-related quality-of-life instrument with a descriptive system (0 to maximum 100 points for best quality of life) [31].

### Functional Assessment: Electromyography

Bipolar surface cup electrodes were used for superficial muscles [22] in a standardized manner parallel to the muscle fibers according to previously described anatomic criteria [25]. All electromyographic examinations and functional tests were performed by one examiner (EJDV) and supervised by a senior neurophysiologist (JHvdH), both of whom were unblinded to rotator cuff status. Monopolar needle electrodes (Ambu A/S, Ballerup, Denmark) were used for intramuscular recording of the activity of the supraspinatus, infraspinatus, and subscapularis muscles. Needle electrodes were inserted aseptically according to the technique described by Basmajian and De Luca [1]. Adequate placement of the electrodes was determined with manual muscle testing, using the previously described tests for each individual muscle [11]. The quality of the recorded muscle activity was checked to ensure that signal-to-noise ratios were correct; poor-quality signals were excluded from analysis. Test-retest was judged to be unnecessary based on previous studies [8, 9].

All electrodes were connected to a 44-channel EEG headbox amplifier/AD converter (Schwarzer AHNS, Heilbronn, Germany) with 100 MOhm input impedance, < 10 kOhm electrode impedance, common mode rejection ratio > 100 dB at 50/60 Hz, sample rate of 1 KHz, band-pass filter of 0.07 Hz and 300 Hz, and 20-bit AD conversion. Signal acquisition, post processing, and analysis were performed on a software system (Onafhankelijke Software Groep, Kontich, Belgium) with BrainRT V3.1 (patch pack 5, build 4201). Raw data were subsequently processed offline using Matlab (R2019a, MathWorks Inc, Natick, MA, USA).

### Testing Protocol

EMG was recorded while the participants performed an adjusted Task 1 of the FIT-HaNSA for 1 minute, so that sufficient repetitive movements were recorded [8]. Synchronized video at 30 frames per second (Sony EP580, Nihonbashi, Tokyo, Japan) was recorded in conjunction with the EMG data, which enabled phase definition for analyzing and determining the shelf contact time.

## Data Management

The signals of the 10 remaining cycles were further processed by applying the root mean square (RMS) (window set 100 ms) [3, 21]. This smooths the signals and makes them positive. We subsequently calculated mean EMG amplitude for each muscle at the group level and normalized to the mean, set to 100%. Because amplitude fluctuates over time, this may result in numbers above and below 100%. Subsequent comparisons between groups were performed by dividing the signals into phases, with exclusion of the shelf contact time expressing the outcome as percentages [8, 9]. The cycle was further averaged with time normalization, resulting in an average activation profile. After screening of the final dataset, we removed outliers based on inconsequential data. We chose the RMS EMG protocol because it reflects a mean activation of a chosen period (phase up and phase down in this study). This is in contrast to other methods where percentages of the maximum voluntary contraction are used, which are less reliable or appropriate for shoulder conditions [9]. Moreover, this is not useful in a testing set-up reflecting daily life.

## Primary and Secondary Outcomes

Our primary study outcome was muscle activation in patients with symptomatic rotator cuff tears using EMG measurements while performing the FIT-HaNSA test. The secondary outcome was the evaluation of coactivation of the shoulder muscles on EMG, while performing the FIT-HaNSA test by calculating the Pearson coefficient between activation profiles.

## Sample Size and Statistical Analysis

Based on the study of Hawkes et al. [9], who used the same FIT-HaNSA protocol for assessment, we calculated a sample size of nine in each group to compare two-mean, two-sample, two-sided equality with an alpha of 5% and power of 0.80. This was based on a score of 100% on Task 1 for the control group and 60% for the rotator cuff tear group, with an SD of 30 and a sampling ratio of 1. Considering a potential loss to follow-up of 20%, we included at least 22 patients.

To quantify the coactivation of the shoulder muscles, we calculated Pearson correlation coefficients for each combination of muscles in each group [23]. This method has sensitivity to detect similarities in the activation pattern, and  $r > 0.70$  is generally considered to indicate a strong, positive relationship [34]. A comparison between muscle groups was deemed of no further benefit because a previous study showed no differences [9].

SPSS statistical software (version 20.0; IBM, Armonk, NY, USA) was used for data compilation and statistical analyses. Demographic and clinical characteristics are



presented as proportions for discrete variables and mean  $\pm$  SD for continuous variables.

After checking for normal distribution and due to small numbers, we decided to present the other clinical outcomes (questionnaires and scores) as median (interquartile range) and mean difference (95% confidence interval). Differences between patients with a rotator cuff tear and control participants were tested using the Mann-Whitney test for non-categorical variables and the Fisher exact test for categorical data.

After confirming normal data distribution (Shapiro-Wilk test), the EMG results have been expressed as the mean  $\pm$  SD. To minimize Type 1 errors, we performed a multivariate ANOVA (MANOVA) to look for significant differences between groups for both phases.

We assessed the statistical significance of differences between participants on the coactivation with a paired t- test. The Benjamini-Hochberg procedure was employed to control for the false discovery rate and showed that p values  $< 0.05$  were considered significant. After removing outliers on EMG data (two patients in the rotator cuff tear group had unsuitable and distorted results), we were able to use the EMG results of 10 patients in the rotator cuff tear group and 11 in the control group for further analysis.

### Patient Characteristics

Patients in the rotator cuff tear group had a mean (range) age of 65  $\pm$  6.2 years (52 to 83), which was comparable to that of the control participants with a mean age of 61  $\pm$  6.2 years (50 to 72;  $p = 0.29$ ) (Table 1). The rotator cuff tear group had impaired shoulder function reflected in a restricted ROM and a median VAS shoulder pain of 55 (IQR 50). Moreover, the rotator cuff tear group reported a lower quality of life compared with the control group (EuroQol-5D-5L scores: rotator cuff tear group median 71 [IQR 33]; control group median 87 [IQR 20]; mean difference 20 [6 to 33];  $p = 0.02$ ). The rotator cuff tear group showed impaired shoulder function with scores lower on the mean FIT-HaNSA than the control group (rotator cuff tear group median 137 [IQR 93] seconds; control group median 300 [0] seconds [maximal score]; mean difference 147 seconds [95% CI 106 to 189];  $p < 0.001$ ). On all three FIT-HaNSA tasks, participants in the rotator cuff tear group scored lower than those in the control group. Also, the rotator cuff tear group had lower CMS and WORC scores compared with the control group. (CMS: rotator cuff tear group median 52 [IQR 37], control group median 100 [IQR 8], mean difference 42 [95% CI 30 to 54];  $p < 0.001$ ; WORC: rotator cuff tear group median 1138 [IQR 919], control group median 81 [IQR 280], mean difference -896 [95% CI -1247 to -544];  $p < 0.001$ ) (Table 2).

**Table 1.** Patient characteristics

Characteristics	Rotator cuff tear group (n = 12)	Control group (n = 11)	p value
Mean age in years $\pm$ SD	64.9 $\pm$ 2.5	61.2 $\pm$ 2.4	0.29 <sup>a</sup>
Sex, n			
Male	6	6	0.48 <sup>b</sup>
Female	6	5	
Investigated arm, n			
Left	4	3	0.55 <sup>b</sup>
Right	8	8	
Smoking, n	1	4	0.16 <sup>b</sup>
Diabetes, n	0	1	0.48 <sup>b</sup>
Rotator cuff tear aspects	Retraction: 10-35 mm Width: 10-25 mm		
SSP, n	7		
SSP and SSC <sup>c</sup> , n	Lafosse Type I: 3 Lafosse Type III: 1		
SSP and ISP, n	1		
Patte stage, n			
1	6		
2	6		
3	0		
Ultrasound, n	3	11	
MRI, n	9	0	

<sup>a</sup>t-test, as normal distributed.

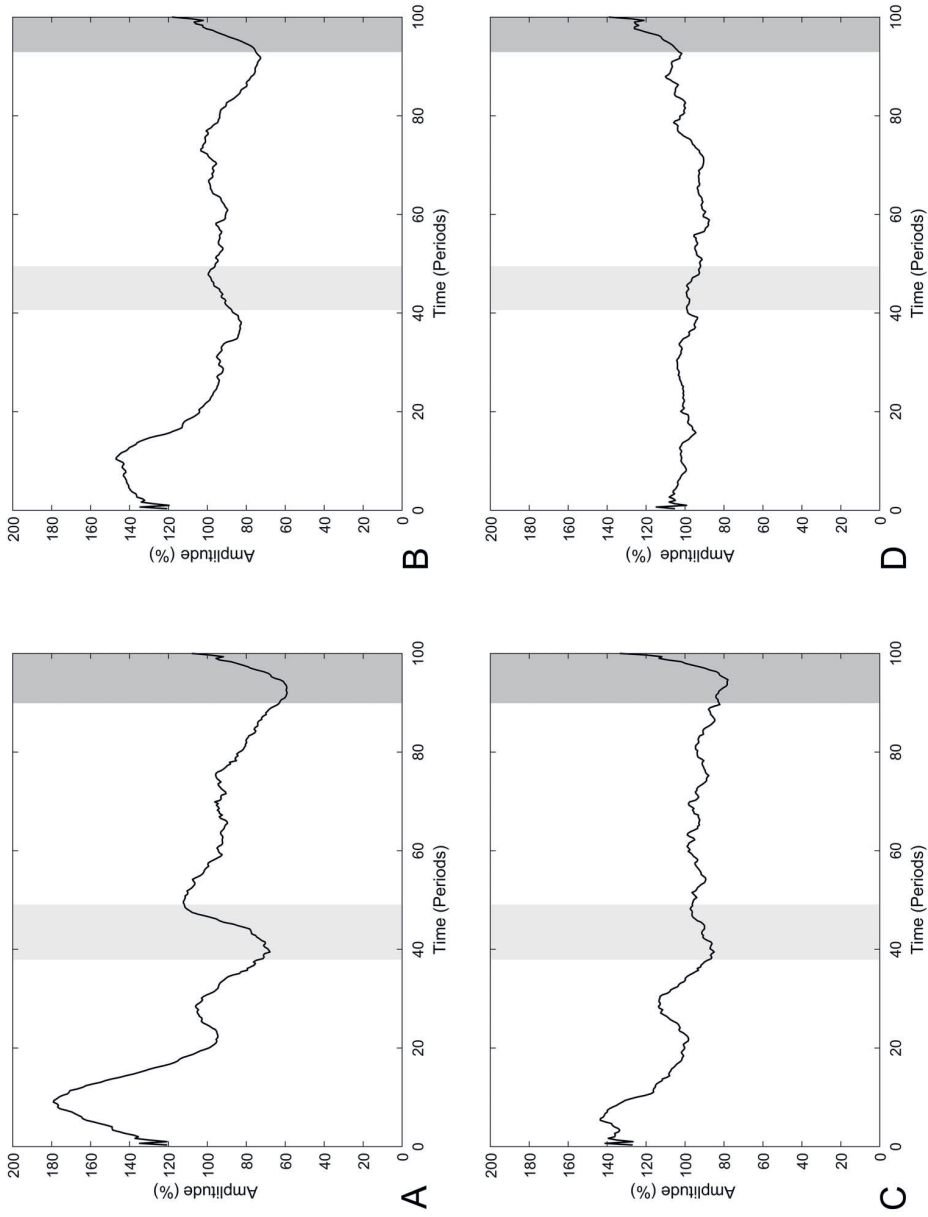
<sup>b</sup>Fisher exact test.

<sup>c</sup>Lafosse classification of subscapularis tendon tears; SSP = supraspinatus; SSC = subscapularis; ISP = infraspinatus.

**Table 2.** Clinical and questionnaire scores

Parameter	RCT group, median (IQR)	Control group, median (IQR)	Mean difference (95% CI)	p value <sup>a</sup>
Anteflexion in °	125 (78)	170 (10)	40 (11 to 69)	0.01
Retroflexion in °	50 (35)	70 (0)	14 (1 to 27)	0.03
Abduction in °	110 (63)	170 (30)	44 (9 to 80)	0.02
External rotation in °	48 (85)	70 (10)	23 (4 to 43)	0.05
Internal rotation, number of patients reaching each level				
Gluteal	2	1	NA	0.49
L5	5	4		
T12	5	6		
FIT-HaNSA Task 1 score	214 (147)	300 (0)	83 (31 to 136)	< 0.001
FIT-HaNSA Task 2 score	68 (87)	300 (0)	206 (155 to 257)	< 0.001
FIT-HaNSA Task 3 score	108 (170)	300 (0)	154 (81 to 227)	< 0.001
Average score all 3 tests (0-300, worst to best score)	137 (93)	300 (0)	147 (106 to 189)	< 0.001
Constant-Murley score (0-100 worst to best score)	52 (37)	100 (8)	42 (30 to 54)	< 0.001
VAS-pain (0 -100 no pain to worst pain)	55 (50)	0 (6)	-49 (-69 to -29)	< 0.001
Total WORC (0-2100: best to worst score)	1138 (919)	81 (280)	-896 (-1247 to -544)	< 0.001
% WORC score	46 (69)	96 (13)	43 (26 to 59)	< 0.001
Physical symptoms (0-600, best to worst score)	359 (234)	39 (60)	-287 (-387 to -188)	< 0.001
Sports and recreation (0-400, best to worst score)	252 (188)	5 (55)	-204 (-282 to -127)	< 0.001
Work (0-400, best to worst score)	297 (113)	17 (50)	-244 (-311 to -175)	< 0.001
Lifestyle (0-400, best to worst score)	189 (224)	5 (80)	-194 (-272 to -118)	< 0.001
Emotions (0-300 best to worst score)	91 (155)	7 (35)	-88 (-150 to -26)	< 0.001
EuroQol-5D-5L score (0-100 worst to best score)	71 (33)	87 (20)	20 (6 to 33)	0.02

<sup>a</sup>p values calculated with a nonparametric test (Mann-Whitney U test); NA = not applicable; FIT-HaNSA = Functional Impairment Test-Hand and Neck/Shoulder/Arm; CMS = Constant Murley score; WORC = Western Ontario Rotator Cuff Index.



**Fig. 1. A-D** Average activation curves for the (A) biceps brachii muscle in the rotator cuff tear group, (B) biceps brachii muscle in the control group, (C) posterior deltoid muscle in the rotator cuff tear group, and (D) posterior deltoid muscle in the control group. The EMG signal amplitude is presented as a function of time. The light gray bars reflect activation during the upper shelf time and the dark bars reflect activation during lower shelf time.

## RESULTS

### EMG Activation

EMG revealed hyperactivity of the posterior deltoid and biceps brachii muscles during the upward phase in patients with rotator cuff tears compared with controls (posterior deltoid: 111%  $\pm$  6.6% versus 102%  $\pm$  6.10%, mean difference -9 [95% CI -17 to -1];  $p = 0.03$ ; biceps brachii: 118%  $\pm$  7% versus 111%  $\pm$  6%, mean difference -7 [95% CI -13 to 0];  $p = 0.04$ ) (Table 3). During the downward phase, there was decreased activity in patients with rotator cuff tears compared with controls (posterior deltoid: 89%  $\pm$  6.6% versus 98%  $\pm$  6.10%, mean difference 9 [95% CI 1 to 17];  $p = 0.03$ ; biceps brachii: 82%  $\pm$  6.7% versus 89%  $\pm$  6.6%, mean difference 7 [95% CI 0 to 14];  $p = 0.03$ ) (Table 4). The mean activation patterns of the posterior deltoid and biceps brachii of both groups are depicted as a line over time (Fig. 1A-D). In the rotator cuff tear group, contraction of the biceps brachii started early, with a high peak in the upward phase and declining at the end of the upward phase (Fig. 1A) compared with the control group (Fig. 1B). Contraction of the posterior deltoid started even earlier in the upward phase and declined at the end of the upward phase in the rotator cuff tear group (Fig. 1C) compared with the control group (Fig. 1D)

**Table 3.** Differences in normalized EMG amplitudes between groups in the upward phase (phase 1)

Muscle	RCT group <sup>a</sup> , mean $\pm$ SD	Control group <sup>b</sup> , mean $\pm$ SD	Mean difference (95% CI)	p value <sup>c</sup>
SSP	103 $\pm$ 12	106 $\pm$ 7	3 (-6 to 12)	0.48
ISP	107 $\pm$ 8	106 $\pm$ 5	-2 (-8 to 5)	0.62
SSC	110 $\pm$ 9	108 $\pm$ 8	-2 (-10 to 6)	0.61
LD	106 $\pm$ 10	103 $\pm$ 5	-3 (-10 to 4)	0.39
PM	112 $\pm$ 9	110 $\pm$ 14	-1 (-13 to 10)	0.80
UT	126 $\pm$ 18	123 $\pm$ 15	-3 (-19 to 13)	0.71
PD	111 $\pm$ 6	102 $\pm$ 10	-9 (-17 to -1)	0.03 <sup>d</sup>
MD	116 $\pm$ 10	111 $\pm$ 10	-5 (-14 to 5)	0.33
AD	118 $\pm$ 9	118 $\pm$ 9	0 (-8 to 9)	0.95
BB	118 $\pm$ 7	111 $\pm$ 6	-7 (-13 to 0)	0.04 <sup>d</sup>

For the SSP, ISP, and SSC in the RCT group, the values are missing for one patient because of complaints about needles but the other EMG outcomes could be used.

<sup>a</sup>Rotator cuff tear group (n = 10); 10 cycles.

<sup>b</sup>Control group (n = 11); 10 cycles.

<sup>c</sup>Based on a MANOVA test.

<sup>d</sup> $p < 0.05$  (statistically significant)

SSP = supraspinatus; ISP = infraspinatus; SSC = subscapularis; LD = latissimus dorsi; PM = pectoralis major; UT = upper trapezius; PD = posterior deltoid; MD = middle deltoid; AD = anterior deltoid; BB = biceps brachii.

## Muscle Coactivation

In the rotator cuff tear group, the posterior deltoid functioned more independently, correlating poorly with the middle deltoid ( $R = 0.00$ ;  $p = 0.94$ ), latissimus dorsi ( $R = -0.07$ ;  $p = 0.20$ ), and biceps brachii ( $R = 0.10$ ;  $p = 0.08$ ). Seven muscle pairs in patients in the rotator cuff tear group showed a strong correlation ( $R > 0.70$ ), and 15 strongly correlating muscle pairs were seen in the control group (Table 5). The anterior deltoid and middle deltoid were coactivated in both groups, but the posterior deltoid seemed to function less in conjunction with the other deltoid muscles in the rotator cuff tear group than in the control group. In the rotator cuff tear group, the posterior deltoid and biceps brachii had a slight relationship. By contrast, the latissimus dorsi showed a strong correlation with the anterior deltoid and middle deltoid muscles.

In the control group, activation of several rotator muscles (supraspinatus, infraspinatus, and subscapularis) were strongly correlated (supraspinatus with infraspinatus and infraspinatus with subscapularis). The rotator muscles were less coactivated in the rotator cuff tear group than in the control group; the supraspinatus was still coactivated with the infraspinatus, but the infraspinatus and subscapularis showed less coactivation. Most muscle pairs showed correlations, except for the posterior deltoid and middle deltoid, posterior deltoid and latissimus dorsi, and posterior deltoid and biceps brachii in the rotator cuff tear group (Appendix 1; Supplemental Digital Content 1, <http://links.lww.com/CORR/A471>). Additionally, in the control group, most muscle pairs had correlations except for the latissimus dorsi with posterior deltoid and the latissimus dorsi with upper trapezius.

**Table 4.** Differences in normalized EMG amplitudes between groups in the downward phase (phase 2)

Muscle	RCT group <sup>a</sup> , mean 6 SD	Control group <sup>b</sup> , mean 6 SD	Mean difference (95% CI)	p value <sup>c</sup>
SSP	98 6 12	94 6 7	-3 (-13 to 6)	0.46
ISP	92 6 8	94 6 5	2 (-5 to 8)	0.58
SSC	90 6 9	92 6 8	2 (-5 to 10)	0.60
LD	94 6 10	97 6 5	3 (-4 to 10)	0.39
PM	89 6 9	90 6 14	1 (-10 to 13)	0.81
UT	74 6 18	77 6 15	3 (-13 to 19)	0.70
PD	89 6 6	98 6 10	9 (1 to 17)	0.03 <sup>d</sup>
MD	84 6 11	89 6 10	5 (-5 to 15)	0.30
AD	81 6 10	82 6 9	0 (-9 to 9)	0.95
BB	82 6 7	89 6 6	7 (0 to 14)	0.03 <sup>d</sup>

For the SSP, ISP, and SSC in the RCT group, the values are missing for one patient because of complaints about needles but the other EMG outcomes could be used.

<sup>a</sup>Rotator cuff tear group (n = 10); 10 cycles.

<sup>b</sup>Control group (n = 11); 10 cycles.

<sup>c</sup>Based on a MANOVA test;

<sup>d</sup> $p < 0.05$  (statistically significant); SSP = supraspinatus; ISP = infraspinatus; SSC = subscapularis; LD = latissimus dorsi; PM = pectoralis major; UT = upper trapezius; PD = posterior deltoid; MD = middle deltoid; AD = anterior deltoid; BB = biceps brachii.

**Table 5.** All muscle pairs with a highly correlated EMG activation pattern

Muscle	Rotator cuff tear group	Control group
AD with	MD, UT, LD	MD, PM, UT, ISP, SSC
MD with	UT, LD	PM, UT, ISP, SSC
PD with		BB
UT with	LD	PM
PM with		ISP, SSC
ISP with	SSP	SSP, SSC

Pearson correlation coefficient  $R > 0.70$ ; AD = anterior deltoid; MD = middle deltoid; PD = posterior deltoid; PM = pectoralis major; UT = upper trapezius; LD = latissimus dorsi; BB = biceps brachii; SSP = supraspinatus; ISP = infraspinatus; SSC = subscapularis.

For full details on all R and p values, see Appendix 1.

## DISCUSSION

Patients with symptomatic rotator cuff tears can retain their shoulder function through compensatory mechanisms. These mechanisms are not fully understood. Previous studies were done in either a static setting or compared with young volunteers. Since functional impairment is the main complaint, it should be tested in a test setting resembling daily life. Muscles and nerves deteriorate with age, therefore, the function should be compared with age-matched controls.

We found that while executing the FIT-HaNSA protocol, patients with a rotator cuff tear compensated with hyperactivity of the posterior deltoid and biceps brachii muscles, as measured with EMG. Less coactivation was seen between the different deltoid muscle parts in the rotator cuff tear patients.

Clinicians might use these findings when treating patients with chronic rotator cuff tears conservatively. The posterior deltoid might be specifically trained to help compensate for a deficient rotator cuff. This study supports the potential benefit of addressing the long head biceps tendon in the treatment of patients with a symptomatic rotator cuff tear. The biceps muscle may be used as a humeral depressor, but this overactivity could induce pain at the long head of the biceps. These results also need to be weighed when considering tenotomy of the long head of the biceps tendon as a pain-relieving intervention in patients with irreparable rotator cuff tears. Future studies should investigate the effect of specific training of the posterior deltoid in patients with a rotator cuff tear. Also, further research on muscle activation and coactivation is needed in patients with a rotator cuff tear who become asymptomatic over time, and these could be compared with patients with a limited function whose rotator cuff tear remains painful.

## Limitations

This study had several limitations. First, the examiner was not blinded, which could lead to a potential bias even though all patients were measured by the senior investigator (EJDV) and assisted by either one of the junior investigators (TES, TdG). Patients were included mostly based on MRI, although three were included based on ultrasound performed by an experienced musculoskeletal radiologist. Sex- and age-related changes exist in nerves [5, 19] and we tried to minimize these effects by matching on age and had an equal sex distribution. Due to the small groups, subgroup analysis was not deemed feasible. Although full MRCTs were excluded, all patients had sizable tears. It might be that smaller tears require less compensation. Testing more periscapular muscles could have been of added value. The EMG protocol and data monitoring were tested and proven in previous studies; therefore, no test-retest reliability was performed [9, 17]. Other potential confounders are the pain some patients had during the insertion of fine needles, which may have altered the movement of the upper limb during the measurements. It would be interesting to test both muscle bellies of the biceps because the medial head may have resulted in crossover signaling. Outliers in the EMG examination consisted of inverted measures or incomplete data, both most likely because of precarious instruments. However, we deemed that removal of this data was necessary.

## EMG Activation

The muscle activation in the rotator cuff tear group was different from that in the control group, with hyperactivity of the posterior deltoid and biceps brachii in the rotator cuff tear group, especially when these participants started to lift a weight. Additionally, in the rotator cuff tear group, the other rotator cuff muscles were not hyperactive but showed less coactivation than those in the control group.

Despite the different study protocols, some results from previous studies could be reproduced, such as hyperactivity of the biceps brachii and posterior deltoid muscles on EMG. The previous shoulder EMG studies examined patients with simulated MRCTs who performed isometric tasks or who were also administered the FIT-HaNSA [8, 9, 28]. These studies saw the recruitment of the latissimus dorsi and teres major muscles as an adduction torque force for opposing deltoid force, thus attempting to stabilize the humeral head. We could not replicate the increased use of the latissimus dorsi in our group of patients with medium-sized rotator cuff tears who performed daily activities, although the pattern strongly correlated with that of the anterior and posterior deltoid muscles, suggesting more synergetic activation. One study suggests that in patients with a rotator cuff tear, the biceps brachii was overactivated because of flexion of the elbow while the arm was lifted to compensate for limited shoulder function [16]. In our results, the biceps brachii was active in the first part of the first phase and was therefore



unlikely to contribute to hyperflexion of the elbow, which in our study occurred at the end of the first phase. This finding supports the idea that the long head of the biceps tendon functions as a depressor [14]. Our results are comparable to those of one of the first studies reporting on this topic, which showed more than 10% hyperactivity of the biceps brachii on EMG in 14 of 40 patients with a rotator cuff tear [13], although this was determined with a different measurement technique in patients with varying rotator cuff tear sizes. Hyperactivity of the biceps brachii was also seen by Hawkes et al. [9] in patients with MRCTs measured with the FIT-HaNSA. Kelly et al. [11] demonstrated that symptomatic patients with a posterosuperior cuff tear have an overactive subscapularis tendon. This was not repeated in the present study; our population included partial tears of the subscapularis tendon and one Lafosse Type 3 tear, which may have altered the activation.

### Muscle Coactivation

Due to impaired rotator cuff function, other muscles compensate to centralize the humeral head during elevation but they do not work together. In the group with a rotator cuff tear, the biceps brachii and posterior deltoid were hyperactive but worked individually using different activation patterns. The posterior deltoid and biceps brachii were highly correlated ( $> 0.70$ ) in the control group, an activation pattern that was not seen in the rotator cuff tear group. The deltoid muscles worked less synergistically in the rotator cuff tear group than in the control group.

Other studies have shown that activation of the subscapularis and infraspinatus compensate for minor supraspinatus tears, but these studies used simulated models that did not reflect activities of daily life, and some had a limited sample size [8, 11]. We did not find an increased activation of the subscapularis and infraspinatus in our rotator cuff tear group. Still, the muscle coactivation in the rotator cuff muscles in patients with a rotator cuff tear was changed. In the control group, rotator cuff muscle activation was strongly correlated. In the group with rotator cuff tears, we observed that, although the supraspinatus and infraspinatus were still coactivated, the subscapularis and infraspinatus showed less coactivation. The subscapularis is the most powerful muscle of the rotator cuff. If the subscapularis and infraspinatus are intact in patients with a supraspinatus tear, they could work together and centralize the humeral head into the socket. This lack of coactivation of the subscapularis could be one of the explanations of why function is limited in patients with rotator cuff tears. Future research should focus on whether selective training, especially of the subscapularis and the posterior deltoid, could lead to more synergistic muscle patterns, offering better pain relief and gain of function. An additional control group of asymptomatic rotator cuff tears would also be of added value.

## CONCLUSION

Patients with impaired shoulder function due to symptomatic rotator cuff tears show compensatory movement patterns based on the abnormal activity of the biceps brachii and posterior deltoid muscles when compared with age-matched controls. The posterior deltoid functions less in conjunction with the other deltoid muscles, and lower coactivation is seen in the remaining intact rotator cuff muscles in the rotator cuff tear group than the control group. Clinicians might use these findings during conservative treatment of patients with chronic rotator cuff tears. The posterior deltoid might be specifically trained to help compensate for the deficient rotator cuff. This study supports the potential benefit of addressing the long head of the biceps tendon in the treatment of patients with symptomatic rotator cuff tears. Further research on muscle activation and coactivation is needed in patients with rotator cuff tears who become asymptomatic over time, and studies should compare these patients with those who have limited function and whose rotator cuff tear remains painful.

## Acknowledgments

We thank Mr. Stefan Kuiper (research assistant, registered nurse) for administrative support and the staff of the clinical neurophysiology laboratory of University Medical Center Groningen for their help.

## REFERENCES

1. Basmajian JV, De Luca CJ. Description and Analysis of the EMG Signal. In: Basmajian JV, ed. *Muscles Alive: Their Functions Revealed by Electromyography*. Williams & Wilkins; 1985.
2. Boileau P, Ahrens PM, Hatzidakis AM. Entrapment of the long head of the biceps tendon: the hourglass biceps—a cause of pain and locking of the shoulder. *J Shoulder Elbow Surg*. 2004;13: 249-257.
3. Burden AM, Trew M, Baltzopoulos V. Normalisation of gait EMGs: a re-examination. *J Electromyogr Kinesiol*. 2003;13: 519-532.
4. Chalmers PN, Cip J, Trombley R, et al. Glenohumeral function of the long head of the biceps muscle: an electromyographic analysis. *Orthop J Sports Med*. 2014;2:2325967114523902.
5. Cioni R, Giannini F, Paradiso C, Battistini N, Navona C, Starita A. Sex differences in surface EMG interference pattern power spectrum. *J Appl Physiol*. 1994;77:2163-2168.
6. Dyrna F, Kumar NS, Obopilwe E, et al. Relationship between deltoid and rotator cuff muscles during dynamic shoulder abduction: a biomechanical study of rotator cuff tear progression. *Am J Sports Med*. 2018;46:1919-1926.
7. Hamada J, Nimura A, Yoshizaki K, Akita K. Anatomic study and electromyographic analysis of the teres minor muscle. *J Shoulder Elbow Surg*. 2017;26:870-877.
8. Hawkes DH, Alizadehkhayat O, Fisher AC, Kemp GJ, Roebuck MM, Frostick SP. Normal shoulder muscular activation and coordination during a shoulder elevation task based on activities of daily living: an electromyographic study. *J Orthop Res*. 2012; 30:53-60.
9. Hawkes DH, Alizadehkhayat O, Kemp GJ, Fisher AC, Roebuck MM, Frostick SP. Shoulder muscle activation and coordination in patients with a massive rotator cuff tear: an electromyographic study. *J Orthop Res*. 2012;30:1140-1146.
10. Keener JD, Galatz LM, Teefey SA, et al. A prospective evaluation of survivorship of asymptomatic degenerative rotator cuff tears. *J Bone Joint Surg Am*. 2015;97:89-98.
11. Kelly BT, Williams RJ, Cordasco FA, et al. Differential patterns of muscle activation in patients with symptomatic and asymptomatic rotator cuff tears. *J Shoulder Elbow Surg*. 2005;14: 165-171.
12. Khandare S, Arce RA, Vidt ME. Muscle compensation strategies to maintain glenohumeral joint stability with increased rotator cuff tear severity: a simulation study. *J Electromyogr Kinesiol*. Published online July 10, 2019. DOI: 10.1016/j.jelekin.2019.07.005.
13. Kido T, Itoi E, Konno N, Sano A, Urayama M, Sato K. Electromyographic activities of the biceps during arm elevation in shoulders with rotator cuff tears. *Acta Orthop Scand*. 1998;69: 575-579.
14. Kido T, Itoi E, Konno N, Sano A, Urayama M, Sato K. The depressor function of biceps on the head of the humerus in shoulders with tears of the rotator cuff. *J Bone Joint Surg Br*. 2000;82:416-419.
15. Kumta P, MacDermid JC, Mehta SP, Stratford PW. The FIT-HaNSA demonstrates reliability and convergent validity of functional performance in patients with shoulder disorders. *J Orthop Sports Phys Ther*. 2012;42:455-464.
16. Levy AS, Kelly BT, Lintner SA, Osbahr DC, Speer KP. Function of the long head of the biceps at the shoulder: electromyographic analysis. *J Shoulder Elbow Surg*. 2001;10:250-255.
17. MacDermid JC, Ghobrial M, Quirion KB, et al. Validation of a new test that assesses functional performance of the upper extremity and neck (FIT-HaNSA) in patients with shoulder pathology. *BMC Musculoskel Disord*. 2007;8:42.
18. McGarry MH, Nguyen ML, Quigley RJ, Hanypsiak B, Gupta R, Lee TQ. The effect of long and short head biceps loading on glenohumeral joint rotational range of motion and humeral head position. *Knee Surg Sports Traumatol Arthrosc*. 2016;24: 1979-1987.

19. Merletti R, Farina D, Gazzoni M, Schieron MP. Effect of age on muscle functions investigated with surface electromyography. *Muscle Nerve*. 2002;25:65-76.
20. Millett PJ, Giphart JE, Wilson KJ, Kagnes K, Greenspoon JA. Alterations in glenohumeral kinematics in patients with rotator cuff tears measured with biplane fluoroscopy. *Arthroscopy*. 2016;32:446-451
21. Morris AD, Kemp GJ, Lees A, Frostick SP. A study of the reproducibility of three different normalisation methods in intramuscular dual fine wire electromyography of the shoulder. *J Electromyogr Kinesiol*. 1998;8:317-322.
22. Nejat N, Mathieu PA, Bertrand M. Investigation on muscle compartments in the biceps brachii. *J Med Biol Eng*. 2012;32: 251-258.
23. Nelson-Wong E, Howarth S, Winter DA, Callaghan JP. Application of autocorrelation and cross-correlation analyses in human movement and rehabilitation research. *J Orthop Sports Phys Ther*. 2009;39:287-295.
24. Neviasser JS. Ruptures of the rotator cuff. *Clin Orthop Relat Res*. 1954;3:92-98.
25. Perotto AO. *Anatomical Guide for the Electromyographer: The Limbs and Trunk*. Charles C. Thomas Publisher; 2011.
26. Rathi S, Taylor NF, Green RA. The effect of in vivo rotator cuff muscle contraction on glenohumeral joint translation: an ultrasonographic and electromyographic study. *J Biomech*. 2016;49: 3840-3847.
27. Spall P, Ribeiro DC, Sole G. Electromyographic activity of shoulder girdle muscles in patients with symptomatic and asymptomatic rotator cuff tears: a systematic review and meta- analysis. *PM&R*. 2016;8:894-906.
28. Steenbrink F, De Groot JH, Veeger H, van der Helm F, Rozing PM. Glenohumeral stability in simulated rotator cuff tears. *J Biomech*. 2009;42:1740-1745.
29. Su W, Budoff JE, Luo Z. The effect of posterosuperior rotator cuff tears and biceps loading on glenohumeral translation. *Arthroscopy*. 2010;26:578-586.
30. Toshiaki A, Itoi E, Minagawa H, et al. Cross-sectional area of the tendon and the muscle of the biceps brachii in shoulders with rotator cuff tears: a study of 14 cadaveric shoulders. *Acta Orthop*. 2005;76:509-512.
31. Versteegh MM, Vermeulen KM, Evers SM, de Wit GA, Prenger R, Stolk EA. Dutch tariff for the five-level version of EQ-5D. *Value Health*. 2016;19:343-352.
32. Von Elm E, Altman DG, Egger M, Pocock SJ, Gøtzsche PC, Vandenbroucke JP. The Strengthening the Reporting of Observational Studies in Epidemiology (STROBE) statement: guidelines for reporting observational studies [published correction appears in *Ann Intern Med*. 2008;148:168]. *Ann Intern Med*. 2007;147:573-577.
33. Wiertsema SH, Rietberg MB, Hekman KM, Schothorst M, Steultjens MP, Dekker J. Reproducibility of the Dutch version of the Western Ontario Rotator Cuff Index. *J Shoulder Elbow Surg*. 2013;22:165-170.
34. Wren TA, Do KP, Rethlefsen SA, Healy B. Cross-correlation as a method for comparing dynamic electromyography signals during gait. *J Biomech*. 2006;39:2714-2718.





**Arthroscopic isolated long head  
of biceps tenotomy in patients  
with degenerative rotator cuff  
tears: mid-term clinical results  
and prognostic factors**

Egbert J.D. Veen  
Ashvin V. Boeddha  
Ronald L. Diercks  
Ydo V. Kleinlugtenbelt  
Ellie B.M. Landman  
Cornelis T. Koorevaar

*European Journal of Orthopaedic Surgery & Traumatology*  
2020, 31(3), 441-448

## ABSTRACT

### Introduction

The long head of biceps tendon is frequently involved in degenerative rotator cuff tears. Therefore, this study explored the clinical results of an isolated biceps tenotomy and identified prognostic factors for improvement in pain and function.

### Materials and methods

Between 2008 and 2017, an arthroscopic isolated biceps tenotomy was performed on 64 patients with a degenerative rotator cuff tear (> 65 years). Primary outcome was patient-perceived improvement in pain and function. Potential prognostic factors for improvement in pain and function were identified.

### Results

A perceived improvement in pain was reported in 78% of the patients at three months after surgery and in 75% at a mean follow-up of 4.2 years (1–7 years;  $n = 55$ ). A perceived improvement in function was observed in 49% of patients at three months and in 76% of patients at follow-up. Patients with a preoperatively normal acromiohumeral distance (>10 mm) reported an improvement in pain and function significantly more often. Retraction of the supraspinatus tendon Patte 3 was significantly associated with worse functional outcome.

### Conclusions

A biceps tenotomy can be a reliable treatment option for patients with symptomatic degenerative cuff tears who fail conservative treatment and have a normal acromiohumeral distance (> 10 mm).

### Keywords

Long head of biceps tendon, Biceps, Tenotomy, Rotator cuff tears, Degenerative, Arthroscopy



## INTRODUCTION

Degenerative rotator cuff tears are common in the ageing population, and most tears are asymptomatic. Some patients may develop symptoms, but conservative treatment is still effective in most cases [1–3]. When conservative treatment fails, operative treatment can be challenging. Although rotator cuff repair is an effective procedure in the younger population, age is associated with less satisfactory results and a higher rate of re-tears [4, 5]. French orthopedic surgeons popularized arthroscopic tenotomy of the long head of biceps tendon (LHB) as a treatment option for patients with degenerative rotator cuff tears [6]. A tenotomy of the long head of biceps is found to produce an earlier pain relief compared to tenodesis [7] and minimal residual symptoms [8]. Also biceps surgery in combination with a rotator cuff repair, superior outcome is seen [9]. Both Walch et al. and Boileau et al. reported satisfactory results after this procedure in patients with degenerative rotator cuff tears who were not willing to participate in a long rehabilitation period after a rotator cuff repair or an irreparable tear [10, 11]. In all these studies the LHB tenotomy is often performed in combination with other procedures, less is known about the effect of an isolated LHB tenotomy. The optimal treatment for individual patients with a rotator cuff tear is still unclear in terms of which patients do well after conservative treatment, which patients benefit from isolated LHB tenotomy and which patients should be preferably treated with a rotator cuff repair. Recent publications show good clinical results in selected cases of rotator cuff repairs in elderly patients [12–14]. Other operative and more invasive treatment options for degenerative cuff tears are procedures like reversed shoulder arthroplasty (RSA), superior capsular reconstruction, lower trapezius tendon transfer and latissimus dorsi muscle transfer. The advantages of an arthroscopic LHB tenotomy are the short operation time, low risks for complications and a limited rehabilitation period compared to the other operative treatment options.

The aim of this study was to explore the clinical results of isolated LHB tenotomy in patients with degenerative rotator cuff tears and to identify potential prognostic factors.

## MATERIALS AND METHODS

### Study design

This is a retrospective longitudinal cohort study.

### Participants

Patients with a degenerative rotator cuff tear treated with an arthroscopic LHB tenotomy between 2008 and 2017 were included. Minimal follow-up was 12 months. Indications for an arthroscopic LHB tenotomy in these patients were a clinically and radiologically confirmed symptomatic degenerative rotator cuff tear, and age above 65 years, and failure of conservative treatment (of at least 6 months) including physiotherapy and cortisone injections, or patients with a symptomatic irreparable rotator cuff tear and failure of conservative treatment (of at least 6 months). Patients with a pseudoparalysis were excluded. Rotator cuff repair was not considered standard treatment for patients above age of 65 years with degenerative rotator cuff tears in our clinic during the study period. Other reconstructive options were considered not suitable, for this, often retired, patient population. If a cuff arthropathy was seen, a RSA was performed. Surgery was performed in a general teaching hospital by two dedicated shoulder surgeons (CK, YK). Patients were excluded when glenohumeral osteoarthritis was observed on plain radiographs, in the case of symptomatic osteoarthritis of the acromioclavicular joint, and if a fracture/dislocation of the operated shoulder occurred during the follow-up period. Approval of the Medical Ethical Committee was obtained (no: 180446), and all patients gave written informed consent. The STROBE guidelines were followed [15].

### Surgical technique

Arthroscopic surgery was performed in beach-chair position under an interscalene block of the brachial plexus. A posterior portal was used to enter the glenohumeral joint, and routine diagnostic arthroscopic evaluation was performed. An anterior working portal was used for instrumentation. Specific details of the rotator cuff and LHB were recorded for each patient. LHBT tenotomy was performed by sectioning the tendon at the origin at the superior labrum with an ablation device. We noted that in hypertrophic LHBs the tendon did not retract out of the glenohumeral joint after sectioning. In those cases, the intra-articular portion of the tendon was resected. No additional surgery was performed in any of the cases. Postoperatively patients wore a collar and cuff for two days, and passive range-of-motion exercises were started immediately. Active mobility exercises were started two days after surgery, as tolerated.

### Outcome measures

Primary outcome was patient-perceived improvement in pain and function after shoulder surgery, measured with two anchor questions in which patients were asked

to indicate on a global rating scale how much their pain (pain anchor) or function (functional anchor) had changed after surgery [16, 17]. The response options for the anchor questions were: completely recovered (7), much improved (6), slightly improved (5), unchanged (4), slightly worse (3), much worse (2) and worse than ever (1). Secondary outcomes were the disabilities of the arm, Shoulder and Hand (DASH) score, VAS pain scores, patient satisfaction, and the EuroQol-5D (EQ-5D). The DASH score is a 30-item, self-report questionnaire designed to measure physical function and symptoms in people with any musculoskeletal disorder of the upper limb [18]. The DASH has been shown to be reliable, valid and responsive in patients with shoulder disability [19] and has been validated in Dutch for patients with a disorder of the upper limb [20]. Pain intensity was measured with the VAS pain score, where a score of 0 points represents no pain and a score of ten points represents unbearable pain. Patients were given a visual scale and were asked to point to the best representation of their pain. VAS pain at rest and VAS pain during activity were obtained. Patient satisfaction was scored by asking the patients whether they were very satisfied, satisfied, somewhat satisfied, disappointed or unhappy with the result of surgery. The EQ-5D is a quality-of-life questionnaire with five questions about mobility, self-care, usual activities, pain/discomfort and anxiety/depression. Five potential prognostic factors were designated: fatty infiltration of the infraspinatus muscle [21], retraction of the supraspinatus tendon, [22] type of LHB lesion, anterosuperior cuff tear [23] and acromiohumeral distance [24]. According to the recommendation of Peduzzi, we selected one candidate prognostic factor for every ten cases [25].

## Data collection

Two weeks prior to elective shoulder surgery, orthopedic patients were seen at an outpatient clinic by an independent physiotherapist. The following preoperative demographic and clinical variables were prospectively collected: age, gender, dominant shoulder and duration of shoulder complaints. The DASH score and the VAS pain score at rest and during activity were scored. After surgery, the following data were recorded: classification of type of LHB lesion [26] and whether the right or left shoulder was operated on. Three months after surgery, improvement in pain and function was scored with anchor questions for all included patients and recorded in the medical reports.

The patients received a print questionnaire at follow-up containing anchor questions about improvement in pain and function, DASH score, VAS pain at rest and during activity, patient satisfaction and the EQ-5D. All follow-up data were collected independently by the research unit of our orthopedic department using standardized case report forms and a study-specific database. If patients were reoperated, they filled in a questionnaire just before the second surgery, including anchor questions about improvement in pain and function, DASH score and VAS pain at rest and during activity.

All second surgeries were considered the endpoint of the follow-up for these patients and were subsequently included in the analysis.

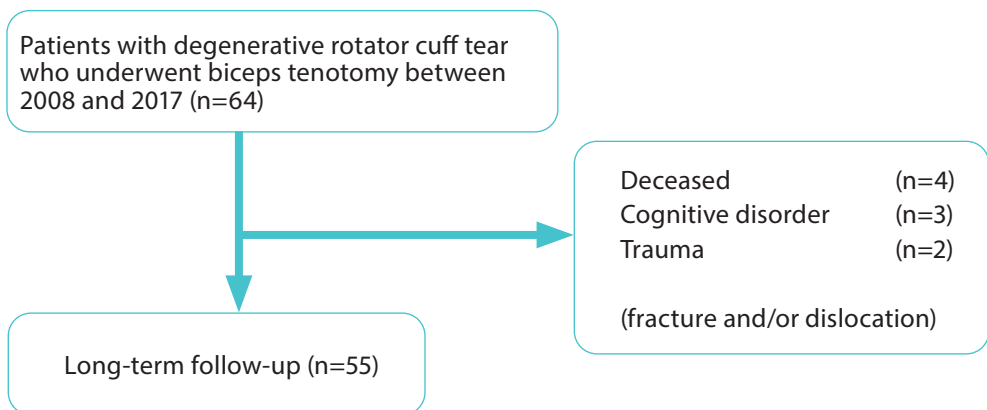
A standard measurement was performed of the acromiohumeral interval on an anteroposterior radiograph with the arm in neutral position. In this study, a modified classification of the acromiohumeral distance according to Saupe et al. [24] was used, considering more than 10 mm a normal acromiohumeral distance.

Retraction of the supraspinatus tendon was scored on an MRI scan using the Patte classification [27], and fatty infiltration of the infraspinatus muscle was scored using the Fuchs classification [28]. If no MRI scan was present before surgery, supraspinatus tendon retraction was scored during arthroscopy.

### Statistical analysis

Patient characteristics are presented as frequency counts and percentages for categorical variables and as mean and standard deviation (SD) for continuous variables. Differences between categorical variables were tested using the Chi-square test and dependent samples t test for continuous variables. IBM SPSS 24 was used for statistical analyses, and  $p$  values of  $< 0.05$  were considered significant.

Five potential prognostic factors were investigated: retraction of the supraspinatus tendon, fatty infiltration of the infraspinatus tendon, presence of LHB lesion, anterosuperior cuff tear, acromiohumeral interval. Potential prognostic factors were first explored using cross tables and Chi-square tests. For comprehensibility and clinical applicability, categorical variables were computed into dichotomous variables. Variables that had significant associations with outcome measures were tested in multiple regression analyses.



**Fig. 1** Inclusion flowchart

## RESULTS

### Description of the study population

The study period included 64 patients. Nine patients were excluded from follow-up: one patient had a traumatic shoulder dislocation with a permanent lesion of the axillary nerve three years after surgery, and one patient sustained a fracture of the proximal humerus one year after surgery. Four patients died before follow-up, and three patients were not able to fill in a postoperative questionnaire due to a cognitive disorder. Figure 1 shows a flow diagram with study enrolment and follow-up.

Of the 55 patients included in the long-term follow-up, mean age was 72.1 years (SD 5.9) at the time of surgery. Demographic, clinical and radiological data at baseline are presented in Table 1. On clinical examination before surgery, no patient in the study population had a pseudoparalysis. An MRI scan was made before surgery in 31 out of 55 patients (56%) and an ultrasound in eight patients (15%). An isolated supraspinatus tear was present in 33 patients (60.0%), a posterosuperior cuff tear in 12 patients (21.8%), an anterosuperior cuff tear in eight patients (18.2%) and a three tendon tear in two patients (3.63%). Retraction of the supraspinatus tendon Patte stage 2 was seen in 15 patients and Patte stage 3 in 22 patients. Fatty infiltration of the infraspinatus muscle grades 'severe' was observed in 21% of patients. Table 2 presents the different LHB tendon lesions observed in the study population. A hypertrophy of the LHB was present in 44% of patients. The presence of a hypertrophic LHB was not associated with retraction of the supraspinatus tendon, two or three ruptured cuff tendons, fatty infiltration of the infraspinatus muscle or acromiohumeral distance.

### Primary outcome

Mean follow-up of these 55 patients was 4.2 years (range 1 to 7 years, SD 2.1). The clinical outcomes of this study are depicted in Table 3. An improvement in pain was reported in 78% of patients three months after surgery and in 75% at follow-up. In one patient, the shoulder deteriorated after a good initial clinical result, with a progression of the cuff tear into a massive cuff tear. An improvement in function was observed in 49% of patients three months after surgery and in 76% of patients at follow-up. Eight patients (15%) were re-operated because of unsatisfactory results after LHB tenotomy: six patients received a reversed shoulder prosthesis and one patient a hemi-shoulder prosthesis, and one patient underwent a latissimus dorsi transfer. No complications were recorded after surgery; one patient developed postoperative stiffness which resolved at follow-up.

## Secondary outcome

Both the preoperative and the long-term follow-up DASH scores were available for 30 patients. A significant improvement in DASH score from 46.1 (SD 17.1) preoperative to 26.5 (SD 22.8) postoperative was observed after an arthroscopic LHB tenotomy ( $p < 0.001$ ). Preoperative and postoperative VAS pain scores were available for 40 patients. Pain during activity improved from VAS 8.2 (SD 1.3) preoperative to VAS 3.0 (SD 3.0) at follow up; 65% of patients were satisfied or very satisfied with the result of surgery, with 15% somewhat satisfied. The EQ-5D score was 0.792 (0.157).

## Prognostic factors

Exploratory analysis showed that patients with an acromiohumeral distance of more than 10 mm reported significantly more often an improvement on the anchor questions for both pain (OR: 7.5, 95% CI: 1.5–37.4) and function (OR: 3.8, 95% CI: 1.1–13.6) at long-term follow-up ( $p = 0.014$  and  $p = 0.042$ ). For pain, there was major improvement or complete recovery in 90% of patients with a normal acromiohumeral distance ( $> 10$  mm) and in 59% of patients with an acromiohumeral distance  $\leq 10$  mm.

Retraction of the supraspinatus tendon Patte grade 1/2 (versus grade 3) was significantly associated with functional improvement (OR: 7.2, 95% CI: 1.6–31.7). Hence, retraction of the supraspinatus tendon negatively influences outcome. No associations between presence of LHB lesion, fatty infiltration of the infraspinatus or anterosuperior cuff tear and anchor questions on pain and function were found. Groups were too small to provide sufficient power for multiple logistic regression analysis. All analyzed factors are depicted in Table 4.

## DISCUSSION

Our study shows good short- and mid-term pain relief was observed after arthroscopic LHB tenotomy in most of the elderly patients with degenerative rotator cuff tears and a failed conservative treatment with improvement on both functional and pain specific questionnaires. Acromiohumeral distance and retraction of the supraspinatus tendon were identified as prognostic factors for pain and function at mid-term follow-up. This is the first study assessing the clinical results after isolated LHB tenotomy in patients with a degenerative cuff rupture. This procedure can be a viable option for patients who are not candidate or do not have access to reconstructive surgery such as rotator cuff repair, superior capsular reconstruction or RSA.

Walch et al. reported satisfactory results in 87% of 307 patients with degenerative rotator cuff tears after arthroscopic LHB tenotomy at 4.7 years follow-up [10]. In that

study, several patients had additional surgery: 36% an acromioplasty and 3% a distal clavicle resection. Boileau et al. reported 78% satisfactory results after 3.5 years follow-up after tenotomy or tenodesis of the LHB in patients with irreparable rotator cuff tears [11]. Patient satisfaction was comparable to the present study: 65% of patients were very satisfied or satisfied, and 15% of patients were somewhat satisfied.

**Table 1** Patient characteristics (*n* = 55)

Age (years), mean (SD)		72.1 (5.9)
Male		21 (38.2%)
Right shoulder		31 (56.4%)
Dominant side		36 (65.5%)
Duration of symptoms (months), mean (SD)		19.9 (25.4%)
Isolated SSP tear		33 (60.0%)
SSP + ISP tears (posterolateral cuff tear)		12 (21.8%)
SSP + subscap tears (anterolateral cuff tear)		8 (18.2%)
SSP + ISP + subscap tears		2 (3.63%)
Supraspinatus tendon retraction (Patte)	Unknown	12 (21.8%)
	Grade 1	6 (10.9%)
	Grade 2	15 (27.3%)
	Grade 3	22 (40.0%)
Infraspinatus muscle fatty infiltration (Fuchs)	Normal	7 (12.7%)
	Moderate	16 (29.1%)
	Severe	6 (10.9%)
Acromiohumeral distance	≤ 10 mm	36 (65.4%)
	> 10 mm	19 (34.5%)

*n* (%) unless otherwise noted, *SD* standard deviation, *SSP* supraspinatus, *ISP* infraspinatus, *Subscap* subscapularis

**Table 2** Classification of long head of biceps tendon lesions (*n* = 55)

Type	Number	Percentage
Type 1: normal	19	(35%)
Type 2: tendinitis	1	(2%)
Type 3: SLAP lesion	0	(0%)
Type 4: partial tendon rupture	3	(6%)
Type 5: total tendon rupture	0	(0%)
Type 6: hypertrophy	24	(44%)
Type 7: subluxation	1	(2%)
Type 8: luxation	6	(11%)
Unknown	1	(2%)

The role of the LHB in shoulder pain has been debated for a long time. Boileau et al. described entrapment of the LHB in patients with degenerative cuff ruptures [29]. They noticed a deformation of the intra-articular portion of the LHB during arthroscopy and

called this the hourglass biceps. The hourglass theory suggests that the hypertrophic intra-articular portion of the LHB leads to entrapment within the joint on elevation of the arm. The intra-articular portion of the tendon buckles and becomes incarcerated within the joint, inhibiting passive and active elevation and causing pain. Hypertrophy of the intra-articular tendon leads to a disproportion between the tendon and the cross-sectional size of the bicipital groove, preventing sliding of the tendon into the groove and leading to its entrapment. Leffert et al. [30] believe that hypertrophy represents a mechanism of functional compensation in the absence of a rotator cuff. Kido et al. [31] suggest the depressor theory and discuss the function of the LHB as a humeral head depressor, as well as its possible hypertrophy in cases of rotator cuff rupture. Our study promotes the idea that the intra-articular part of the LHB tendon plays role in the pain of patients with a symptomatic rotator cuff tear.

**Table 3** Clinical outcome scores

	Preoperative	Short-term follow-up <i>n</i> = 55 (3 months post-op)	Long-term follow-up <i>n</i> = 55 (mean 4.2 years)	<i>p</i> value
Anchor question pain, <i>n</i> (%)				
Completely recovered (7)		13 (23.6%)	15 (27.3%)	
Much improved (6)		23 (41.8%)	23 (41.8%)	
Slightly improved (5)		7 (12.7%)	3 (5.5%)	
Unchanged (4)		12 (21.8%)	10 (18.2%)	
Slightly worse (3)		–	1 (1.8%)	
Much worse (2)		–	3 (5.5%)	
Worse than ever (1)		–	–	
Anchor question function, <i>n</i> (%)				
Completely recovered (7)		3 (5.5%)	13 (23.6%)	
Much improved (6)		18 (32.7%)	22 (40.0%)	
Slightly improved (5)		6 (10.9%)	7 (12.7%)	
Unchanged (4)		24 (43.6%)	9 (16.4%)	
Slightly worse (3)		3 (5.5%)	1 (1.8%)	
Much worse (2)		1 (1.8%)	3 (5.5%)	
Worse than ever (1)		–	–	
DASH score ( <i>n</i> = 30), mean (SD)	46.1 (17.1)		26.5 (22.8)	<i>p</i> < 0.001
VAS pain activity ( <i>n</i> = 40), mean (SD)	8.2 (1.3)		3.0 (3.0)	<i>p</i> < 0.001
VAS pain rest ( <i>n</i> = 40), mean (SD)	2.6 (1.9)		1.7 (2.3)	<i>p</i> = 0.045
Patient satisfaction, <i>n</i> (%)				
Very satisfied			20 (36.4%)	
Satisfied			16 (29.1%)	
Somewhat satisfied			8 (14.5%)	
Disappointed			6 (10.9%)	
Unhappy			5 (9.1%)	
EQ-5D total score, mean (SD)			0.792 (0.157)	

*SD* standard deviation



**Table 4.** Prognostic factors and clinical outcome

	Anchor pain $\geq 6$			Anchor function $\geq 6$		
	OR	95% CI	P value	OR	95% CI	P value
Supraspinatus retraction (Patte 1/2)			NS	7.2	(1.6–31.7)	$P = 0.009$
ISP fatty infiltration (Fuchs 3)			NS			NS
Biceps tendon lesion			NS			NS
AH distance ( $> 10$ mm)	7.5	(1.5–37.4)	$p = 0.014$	3.8	(1.1–13.6)	$p = 0.042$
Anterosuperior cuff tear			NS			NS

NS not significant, CI confidence interval, OR odds ratio, AH acromiohumeral Anchor score 6: much improved Anchor score 7: completely recovered

Acromiohumeral distance appeared to be of great importance in treating patients with symptomatic degenerative rotator cuff tears. Patients in the current study with a normal acromiohumeral distance ( $> 10$  mm) reported significantly better improvement in pain and function after LHB tenotomy than patients with a shorter acromiohumeral distance ( $\leq 10$  mm), irrespective of type of LHB lesion. Saupe et al. [24] studied acromiohumeral distance in patients with rotator cuff tears and used three groups: group 1 with a normal acromiohumeral distance ( $> 10$  mm), group 2 with an acromiohumeral distance between 7 and 10 mm and group 3 with an acromiohumeral distance  $\leq 7$  mm. They observed that acromiohumeral distance correlated with size of the rotator cuff tear and degree of fatty degeneration of the infraspinatus muscle. Walch et al. observed superior results after LHB tenotomy in patients with an acromiohumeral distance greater than 6 mm and an association of fatty infiltration of the rotator cuff musculature with inferior results after biceps tenotomy [10]. In our study, the group of patients with an acromiohumeral distance of 7 mm or less was too small to make any comparison. Based on the studies mentioned above, it was decided to compare between more and less than 10 mm.

Limitations were the retrospective study design and the absence of a control group. The pain relief observed after LHB tenotomy could be the result of the tenotomy but might also be attributable to a surgical placebo effect, to the postoperative treatment of the physiotherapist or to a benign natural course. Patients included in this study had symptoms for a long period (mean duration of 19.9 months), and most patients were already being extensively treated by a physiotherapist before surgery. Interestingly, the pain relief after LHB tenotomy was already observed within three months postsurgery and was maintained at longer follow-up. This supports the concept of the LHB as a pain generator in patients with a degenerative cuff tear. Furthermore, the improvement in 19.6 points on the DASH score exceeds the minimal important clinical difference (MICD) of 10.8 points [32]. In this study, we used anchor questions as specific questions about pain and functional improvement after surgery. Patients were asked in a single question to indicate how much their function or pain had changed since baseline. The anchor questions may be affected by recall bias [33]. Tashjian and colleagues classified

these anchor questions as retrospective assessment of outcome improvement [34]. They compared prospective and retrospective assessment of functional outcome after rotator cuff repair. Retrospective assessment had fair correlations with prospectively determined improvement, for example with the DASH score. Patient satisfaction was more highly correlated with retrospective evaluations than with prospective improvement in functional outcome measures. Moreover, we have to consider possible confounding biases of the prognostic factors. The acromiohumeral distance will be more narrowed in patients with a much retracted supraspinatus and fatty infiltration of the infraspinatus. However, groups were too small to provide sufficient power for multiple logistic regression analysis.

## CONCLUSION

Arthroscopic long head of biceps tenotomy in patients with degenerative cuff tears and failed conservative treatment can be a reliable treatment option when the acromiohumeral distance is normal ( $> 10$  mm), with both good short- and mid-term pain relief and functional outcomes. Other treatment options should be considered when the acromiohumeral distance is shorter in patients with degenerative cuff tears.

## REFERENCES

1. Moosmayer S, Lund G, Seljom US, Haldorsen B, Svege IC, Hennig T et al (2014) Tendon repair compared with physiotherapy in the treatment of rotator cuff tears: a randomized controlled study in 103 cases with a five-year follow-up. *JBJS* 96(18):1504–1514
2. Kukkonen J, Joukainen A, Lehtinen J, Mattila KT, Tuominen EK, Kauko T et al (2015) Treatment of nontraumatic rotator cuff tears: a randomized controlled trial with two years of clinical and imaging follow-up. *JBJS* 97(21):1729–1737
3. Heerspink FOL, van Raay JJ, Koorevaar RC, van Eerden PJ, van't Westerbeek RE, Riet E et al (2015) Comparing surgical repair with conservative treatment for degenerative rotator cuff tears: a randomized controlled trial. *J Shoulder Elbow Surg* 24(8):1274–1281
4. Hein J, Reilly JM, Chae J, Maerz T, Anderson K (2015) Retear rates after arthroscopic single-row, double-row, and suture bridge rotator cuff repair at a minimum of 1 year of imaging follow-up: a systematic review. *Arthroscopy* 31(11):2274–2281
5. Galatz LM, Ball CM, Teefey SA, Middleton WD, Yamaguchi K (2004) The outcome and repair integrity of completely arthroscopically repaired large and massive rotator cuff tears. *JBJS* 86(2):219–224
6. Szabo I, Boileau P, Walch G (2008) The proximal biceps as a pain generator and results of tenotomy. *Sports Med Arthrosc Rev* 16(3):180–186
7. Watson ST, Robbins CB, Bedi A, Carpenter JE, Gagnier JJ, Miller BS (2017) Comparison of outcomes 1 year after rotator cuff repair with and without concomitant biceps surgery. *Arthroscopy* 33(11):1928–1936
8. Belay ES, Wittstein JR, Garrigues GE, Lassiter TE, Scribani M, Goldner RD, Bean CA (2019) Biceps tenotomy has earlier pain relief compared to biceps tenodesis: a randomized prospective study. *Knee Surg Sports Traumatol Arthrosc* 27(12):4032–4037
9. Meeks BD, Meeks NM, Froehle AW, Wareing E, Bonner KF (2017) Patient satisfaction after biceps tenotomy. *Orthop J Sports Med* 5(5):2325967117707737
10. Walch G, Edwards TB, Boulahia A, Nové-Josserand L, Neyton L, Szabo I (2005) Arthroscopic tenotomy of the long head of the biceps in the treatment of rotator cuff tears: clinical and radiographic results of 307 cases. *J Shoulder Elbow Surg* 14(3):238–246
11. Boileau P, Baqué F, Valerio L, Ahrens P, Chuinard C, Trojani C (2007) Isolated arthroscopic biceps tenotomy or tenodesis improves symptoms in patients with massive irreparable rotator cuff tears. *JBJS* 89(4):747–757
12. Jacquot A, Dezaly C, Goetzmann T, Roche O, Sirveaux F, Molé D et al (2014) Is rotator cuff repair appropriate in patients older than 60 years of age? Prospective, randomised trial in 103 patients with a mean four-year follow-up. *Orthop Traumatol Surg Res* 100(6):S338
13. Rhee YG, Cho NS, Yoo JH (2014) Clinical outcome and repair integrity after rotator cuff repair in patients older than 70 years versus patients younger than 70 years. *Arthrosc J Arthrosc Relat Surg* 30(5):546–554
14. Bhatia S, Greenspoon JA, Horan MP, Warth RJ, Millett PJ (2015) Two-year outcomes after arthroscopic rotator cuff repair in recreational athletes older than 70 years. *Am J Sports Med* 43(7):1737–1742
15. Von Elm E, Altman DG, Egger M, Pocock SJ, Gøtzsche PC, Vandenbroucke JP et al (2007) The strengthening the reporting of observational studies in epidemiology (STROBE) statement: guidelines for reporting observational studies. *PLoS Med* 4(10):e296
16. de Vet HC, Terwee CB, Mokkink LB, Knol DL (2011) *Measurement in medicine: a practical guide*. Cambridge University Press, Cambridge
17. de Vet HC, Terwee CB, Knol DL, Bouter LM (2006) When to use agreement versus reliability measures. *J Clin Epidemiol* 59(10):1033–1039

18. Hudak PL, Amadio PC, Bombardier C, Beaton D, Cole D, Davis A et al (1996) Development of an upper extremity outcome measure: the DASH (disabilities of the arm, shoulder, and hand). *Am J Ind Med* 29(6):602–608
19. Desai AS, Dramis A, Hearnden AJ (2010) Critical appraisal of subjective outcome measures used in the assessment of shoulder disability. *Ann R Coll Surg England* 92(1):9–13
20. Veehof MM, Slegers EJ, van Veldhoven NH, Schuurman AH, van Meeteren NL (2002) Psychometric qualities of the dutch language version of the disabilities of the arm, shoulder, and hand questionnaire (DASH-DLV). *J Hand Ther* 15(4):347–354
21. Cheung S, Dillon E, Tham S, Feeley BT, Link TM, Steinbach L et al (2011) The presence of fatty infiltration in the infraspinatus: its relation with the condition of the supraspinatus tendon. *Arthrosc J Arthrosc Relat Surg* 27(4):463–470
22. Meyer DC, Wieser K, Farshad M, Gerber C (2012) Retraction of supraspinatus muscle and tendon as predictors of success of rotator cuff repair. *Am J Sports Med* 40(10):2242–2247
23. Saccomanno MF, Sircana G, Cazzato G, Donati F, Randelli P, Milano G (2016) Prognostic factors influencing the outcome of rotator cuff repair: a systematic review. *Knee Surg Sports Traumatol Arthrosc* 24(12):3809–3819
24. Saupe N, Pfirrmann CW, Schmid MR, Jost B, Werner CM, Zanetti M (2006) Association between rotator cuff abnormalities and reduced acromiohumeral distance. *Am J Roentgenol* 187(2):376–382
25. Peduzzi P, Concato J, Kemper E, Holford TR, Feinstein AR (1996) A simulation study of the number of events per variable in logistic regression analysis. *J Clin Epidemiol* 49(12):1373–1379
26. Chen C, Chen C, Chang C, Su C, Wang K, Wang I et al (2012) Classification and analysis of pathology of the long head of the biceps tendon in complete rotator cuff tears. *Chang Gung Med J* 35(3):263–270
27. Patte D (1990) Classification of rotator cuff lesions. *Clin Orthop* 254:81–86
28. Fuchs B, Weishaupt D, Zanetti M, Hodler J, Gerber C (1999) Fatty degeneration of the muscles of the rotator cuff: assessment by computed tomography versus magnetic resonance imaging. *J Shoulder Elbow Surg* 8(6):599–605
29. Boileau P, Ahrens PM, Hatzidakis AM (2004) Entrapment of the long head of the biceps tendon: the hourglass biceps—a cause of pain and locking of the shoulder. *J Shoulder Elbow Surg* 13(3):249–257
30. Leffert RD, Rowe CR (1988) Tendon rupture. In: Rowe CR (ed) *The shoulder*. Churchill Livingstone, New York, pp 133–163
31. Kido T, Itoi E, Konno N, Sano A, Urayama M, Sato K (2000) The depressor function of biceps on the head of the humerus in shoulders with tears of the rotator cuff. *J Bone Joint Surg Br* 82(3):416–419
32. Franchignoni F, Vercelli S, Giordano A, Sartorio F, Bravini E, Ferriero G (2014) Minimal clinically important difference of the disabilities of the arm, shoulder and hand outcome measure (DASH) and its shortened version (QuickDASH). *J Orthop Sports Phys Ther* 44(1):30–39
33. Crosby RD, Kolotkin RL, Williams GR (2003) Defining clinically meaningful change in health-related quality of life. *J Clin Epidemiol* 56(5):395–407
34. Tashjian RZ, Bradley MP, Tocci S, Henn RF, Rey J, Green A (2008) A comparison of prospective and retrospective assessment of functional outcome after rotator cuff repair. *J Shoulder Elbow Surg* 17(6):853–859





**Biceps autograft augmentation**  
**for rotator cuff repair:**  
**a systematic review**

Egbert J.D. Veen  
Martin Stevens  
Ronald L. Diercks

*Arthroscopy: The Journal of Arthroscopic & Related Surgery*  
2018, 34(4), 1297-1305.

## ABSTRACT

### **Purpose**

To improve surgical outcomes in patients with massive cuff defects, different techniques and augmentations are proposed. The biceps tendon is easily available as an autograft. Our aim was to conduct a qualitative systematic review of various methods and surgical techniques that use a biceps autograft (BAG) for rotator cuff repair. Functional outcomes are also reported. We hypothesized that by using a BAG to treat massive rotator cuff tears, a more anatomic and biomechanical reconstruction could be achieved compared with other techniques.

### **Methods**

A qualitative systematic review was conducted (MEDLINE and Embase databases) to inventory surgical techniques for use of a BAG for rotator cuff repair. The following search terms were used for MEDLINE: biceps AND (augment\* OR autograft\* OR transplantation\* OR (cuff AND graft\*) OR biceps-incorporat\*). Studies were included if the following criteria were fulfilled: description of surgical technique, only human subjects, functional outcomes noted, all study designs except technical notes, and no restrictions on study date. The quality of the studies was assessed in a standardized manner using a tool based on the Cochrane handbook.

### **Results**

We identified 981 studies; among these, 8 case series met the inclusion criteria. We identified 6 studies as high quality and 2 as medium quality. Different techniques for harvest and augmentation were used. Some studies left the proximal or distal portion intact, whereas others used it as a free graft. The clinical results of these studies showed significantly improved function, pain relief, and range of motion at follow-up, although this was not compared with a control group. The constructs were intact on magnetic resonance imaging in most patients (82%) within 2 years.

### **Conclusions**

It can be concluded that use of a BAG is an option for augmentation in massive rotator cuff tears, although no definitive recommendations can be given. This is based on Level IV medium- and high-quality studies.

### **Level of Evidence**

Level IV, systematic review of Level IV studies.



## INTRODUCTION

Massive cuff tears can be challenging to repair because of retraction, fatty infiltration, and defect size. In comparative studies, the mean outcomes of patient groups after rotator cuff repair were similar to those of patient groups in which conservative treatment was maintained.<sup>1,2</sup> Given that successful healing rates from 27% to 74% have been reported, the incidence of retears or incomplete healing is high.<sup>3</sup> Better outcomes are associated with successful restoration of the rotator cuff integrity compared with failed or incomplete healing of cuff repairs.<sup>1</sup>

Several techniques have been proposed to improve the outcome of cuff repairs, such as the use of anchors, in a single or double row; bone morphogenetic proteins (BMPs); platelet-rich plasma (PRP); scaffolds; and muscle transfers. All have shown inconsistent results.<sup>4-9</sup> Autografts can be used to replace or reinforce ruptured tendons. A method to treat rotator cuff deficiency is the use of the intra-articular portion of the biceps tendon for rotator cuff repair. This biceps autograft (BAG) technique has several advantages: It is available in most patients; because it is an autograft, there are no immune reactions; it is relatively easy to harvest during the same (arthroscopic) procedure; and it is rich in tenocytes and fibroblasts.<sup>10</sup>

Our aim was to conduct a qualitative systematic review of various methods and surgical techniques that use a BAG for rotator cuff repair. Functional outcomes are also reported. We hypothesized that by using a BAG to treat massive rotator cuff tears, a more anatomic and biomechanical reconstruction could be achieved compared with other techniques.

## METHODS

### Literature Search

We conducted a systematic search of the literature by using the online databases MEDLINE and Embase according to Preferred Reporting Items for Systematic Reviews and Meta-analyses guidelines.<sup>11</sup> For this study, we developed a systematic review protocol that was added to the PROSPERO database (No. 51299).

### Study Selection

The following search terms were used for MEDLINE: biceps AND (augment\* OR autograft\* OR transplantation\* OR (cuff AND graft\*) OR biceps-incorporat\*). For Embase, other search terms were used because different instructions are needed to achieve an optimal result: biceps\* AND (augment\* OR autograft\* OR transplantation\* OR (cuff\* AND graft\*) OR biceps NEAR/5 incorporat\*). All publications had to meet the following

general inclusion criteria for selection: publications about the use of a BAG for rotator cuff repair; description of surgical technique; only human subjects included (cadavers allowed); functional outcomes noted but not required; all study designs except technical notes; no restrictions on study date; and languages restricted to English, German, and Dutch because the authors are familiar with these languages.

Nonblinded standardized literature appraisal was conducted independently by 2 reviewers (E.J.D.V. and R.L.D.). All duplicates were removed after the literature searches. The abstracts and titles were scanned, and any disagreements between reviewers were resolved by consensus. The reference lists of all selected publications were manually checked to retrieve relevant publications that had not been found in the primary search. The reviewers independently checked the full texts of the remaining articles for eligibility.

**Table 1.** Quality Assessment Questions

Category	Question	Rating
Study purpose	1. Was the purpose clearly stated?	+, -
Literature	2. Was the relevant background reviewed?	+, -
Sample	3. Was the sample described in detail?	+, -
	4. Was the sample size justified?	+, -, NA
Outcomes	5. Were the outcome measures reliable?	+, -, NA
	6. Were the outcome measures valid?	+, -, NA
Intervention	7. Was the intervention described in detail?	+, -, NA
	8. Was contamination avoided?	+, -, NA
	9. Was co-intervention avoided?	+, -, NA
Results	10. Were the results reported in terms of statistical significance?	+, -, NA
	11. Where the analysis methods appropriate?	+, -, NA
	12. Was clinical importance reported?	+, -
	13. Were dropouts reported?	+, -
Conclusions	14. Were conclusions appropriate, given study methods and results?	+, -

NA, not applicable.

\*Variables were rated as positive or yes (plus sign), negative or no (minus sign), or NA.

## Quality Assessment

A tool based on the Cochrane Collaboration handbook and further developed by the McMaster University School of Rehabilitation Science was used to assess reporting quality.<sup>12,13</sup> The quality assessment consists of 16 questions distributed into 9 categories that give an impression of the risk of bias: citation, study purpose, literature, design, sample, outcomes, intervention, results, and conclusions and implications. This method is considered appropriate to assess randomized controlled trials, cohort studies, single-case designs, before-and-after designs, case-control studies, cross-sectional studies, and case studies. Each quality item is answered yes, no, or “not applicable”. Each item

is also provided with supplementary information to substantiate the choices made.<sup>14</sup> In this study the citation and design categories were removed from the list because they are only descriptive and are already displayed in the characteristics, leaving 14 questions (Table 1). Two authors (E.J.D.V. and R.L.D.) independently assessed the included studies. In a consensus meeting any differences were resolved by discussion and settled by a third reviewer (M.S.). The maximum score obtainable was 14. An arbitrary grading score was created: Studies were regarded to be of high quality when the sum score was 8 or higher, regardless of study type.<sup>23</sup> Studies with a score between 5 and 7 were regarded to be of medium quality, and scores of 4 or lower identified low-quality studies.

## Data Analysis

A general study analysis form was used to extract data. The surgical technique was analyzed by focusing on 2 aspects: the method of proximal harvest of the graft and the method of distal harvest and/or method of fixation. Descriptive data such as patient characteristics and functional outcome scores were displayed with means and, when possible, their standard deviations. The overall agreement in the quality assessment between the 2 reviewers was calculated with a weighted Cohen k coefficient.

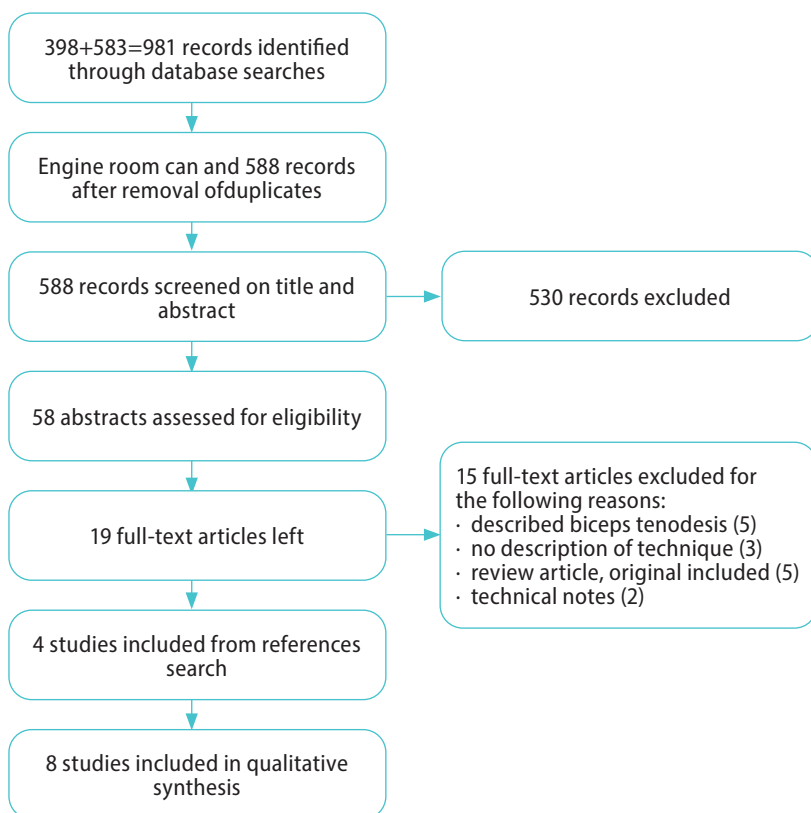


Fig 1. Flowchart of data selection.

## RESULTS

### Study Selection

The search strategy identified 981 potentially eligible citations (398 in MEDLINE and 583 in Embase). After removal of duplicates, a total of 588 titles were screened for eligibility (as detailed in the flowchart shown in Fig 1). After screening, 48 abstracts were analyzed; of these, 19 seemed suitable, and their full texts were reviewed for eligibility. Two studies used a BAG technique but had technical notes, so they were excluded.<sup>24,25</sup> Eventually, 8 studies met all the criteria and were included.<sup>15-22</sup> Because of incomplete data, no meta-analysis could be conducted. When the search was repeated on June 23, 2016, no additional publications of interest were found.

### Methodologic Quality

All 8 studies were case series. Two studies had partial overlap of the patient population but were reviewed separately.<sup>19,20</sup> The overlap accounted for a maximum of 16 patients treated arthroscopically in the study of Rhee et al.,<sup>19</sup> who were also part of a group of 37 arthroscopically treated patients in the study of Cho et al.<sup>20</sup> The overall agreement between the 2 reviewers for the 14 items applied to the 8 publications was considered fair (weighted Cohen k coefficient, 0.346 0.058 [standard error]). Disagreements arose mainly for items 8, 9, 10, 11, and 14. All of these were resolved after the consensus meeting. The percentages of the maximum attainable score ranged from 38% to 86%. A total of 6 studies were considered high quality,<sup>17-22</sup> and 2 studies were categorized as medium quality.<sup>15,16</sup> The outcome of the methodologic quality assessment of the studies is presented in Table 2.

### Study Characteristics

Table 3 shows the characteristics of the studies. The total number of patients was 170, with the mean age ranging from 55 to 64 years. The first study to describe a surgical technique using the biceps tendon for rotator cuff repair was published in 1974.<sup>16</sup> The largest case series consisted of 37 patients.<sup>20</sup> In half of the studies, an open cuff repair was performed; in the other half, the procedure was arthroscopic. All studies mentioned "massive cuff tears," but only 3 defined these by identifying tears of at least 3 or 5 cm.<sup>19,20,22</sup> The mean follow-up period ranged from 9.8 to 40.7 months

**Table 2, Quality Assessment**

Study	Item 1 (Study Purpose)	Item 2 (Literature)	Item 3 (Sample)	Item 4 (Sample)	Item 5 (Outcomes)	Item 6 (Outcomes)	Item 7 (Interventions)	Item 8 (Interventions)	Item 9 (Interventions)	Item 10 (Results)	Item 11 (Results)	Item 12 (Results)	Item 13 (Results)	Item 14 (Conclusions)	Total score	%
Neviaser, <sup>15</sup> 1971	+	-	+	-	-	-	+	NA	+	NA	-	+	-	+	6	50
Wolfgang, <sup>16</sup> 1974	-	+	+	-	-	-	+	NA	-	-	-	+	-	+	5	38
Guyen et al., <sup>17</sup> 2001	+	-	+	-	+	+	+	NA	+	-	-	+	-	+	8	62
Pavlidis et al., <sup>18</sup> 2002	+	+	+	-	+	+	+	NA	+	-	-	+	-	+	9	69
Rhee et al., <sup>19</sup> 2008	+	+	+	-	+	+	+	+	+	+	+	+	-	+	12	86
Cho et al., <sup>20</sup> 2009	+	+	+	-	+	+	+	+	+	+	+	+	-	+	12	86
Sano et al., <sup>21</sup> 2010	+	+	+	-	+	+	+	NA	+	+	+	+	-	+	11	85
Ji et al., <sup>22</sup> 2014	+	+	+	-	+	+	+	+	+	+	+	+	-	+	12	86

NOTE: Every question could be answered yes (plus sign) or no (minus sign). Some questions were not applicable and therefore were answered NA; these are excluded in the total score. The rightmost columns depict the total scores and percentages of maximum attainable scores.

**Table 3, Studies Included**

Study	Design	Level of evidence	No. of patients	Mean age, yr	FU*	Open vs Arthroscopy	Defect size	Acromioplasty	Biceps Harvest Technique
Neviaser, <sup>15</sup> 1971	case series	IV	10	55	4-30	Open	NN	NN	Tenotomy Tenodesis*
Wolfgang <sup>16</sup> 1974	case series	IV	14	55	9.8	Open	NN	When indicated	Tenotomy Tenodesis*
Guyen et al., <sup>17</sup> 2001	case series	IV	14	60	41	Open	NN	Yes	Tenotomy Tenodesis*
Pavlidis et al., <sup>18</sup> 2002	case series	IV	15	55	23	Open	NN	NN	Tenotomy Tenodesis*
Rhee et al., <sup>19</sup> 2008	case series	IV	31	59	16	Arthroscopy in 16 and open in 15	>5 cm	When indicated	Tenotomy Tenodesis*
Cho et al., <sup>20</sup> 2009	case series	IV	37	60	21	Arthroscopy	>5 cm	When indicated	Tenotomy Tenodesis*
Sano et al., <sup>21</sup> 2010	case series	IV	14	64	28	Open	>5 cm	Yes	Tenotomy Tenodesis*
Ji et al., <sup>22</sup> 2014	case series	IV	35	62	24	Arthroscopy	>3 cm	Yes	Tenotomy Tenodesis*

FU, follow-up; NN, not noted.

\* The biceps tendon was tenotomized at the insertion of the glenoid, and the humeral part of the tendon was fixated.

Table 4. Clinical Outcome Scores

Study	Clinical Score	Before	Range	SD	After	Range	SD
Neviaser, <sup>15</sup> 1971	-	-	-	-	Improved	-	-
Wolfgang, <sup>16</sup> 1974	-	-	-	-	Not noted	-	-
Guyen et al., <sup>17</sup> 2001	CMS	46.7	-	2.526	75.35	-	4.129
Pavlidis et al., <sup>18</sup> 2003	CMS	-	-	-	82.7	-	-
Rhee et al., <sup>19</sup> 2008	CMS	48.4	8-70	-	81.8	37-96	-
	UCLA	12.5	6-19	-	31.1	9-35	-
	SST	4.2	1-8	-	10.2	8-12	-
Cho et al., <sup>20</sup> 2009	CMS	38.5	-	-	82.6	69-95	-
	UCLA	14.1	6-12	-	32.6	22-35	-
Sano et al., <sup>21</sup> 2010	JOA	54.7	-	9.3	83.1	-	7.5
Ji et al., <sup>22</sup> 2014	UCLA	18.4	-	4.4	31.3	-	2.5
	SST	6.2	-	2.4	9.0	-	9.6
	ASES	52.4	-	16.7	86.6	-	6.7

ASES, American Shoulder and Elbow Surgeons score; CMS, Constant-Murley score; JOA, Japanese Orthopaedic Association shoulder score; SD, standard deviation; SST, Simple Shoulder Test; UCLA, University of California, Los Angeles score.

Table 5. Range of Motion

Study	Forward Flexion, °		External Rotation, °		Abduction, °		Internal Rotation		Improvement
	Before	After	Before	After	Before	After	Before	After	
Neviaser, <sup>15</sup> 1971	-	-	-	-	145	152	-	-	Improved
Wolfgang, <sup>16</sup> 1974	-	-	-	-	-	-	-	-	Not noted
Guyen et al., <sup>17</sup> 2001	47.5	142.8	13.2	51.1	-	-	T12	T12	Significant improvement
Pavlidis et al., <sup>18</sup> 2003	-	-	-	-	-	-	-	-	Not noted
Rhee et al., <sup>19</sup> 2008	126	162	38	47	134	168	L1	T10	Significant improvement
Cho et al., <sup>20</sup> 2009	131.6	156.2	36.8	47.0	140	162	T12	T11	Significant improvement
Sano et al., <sup>21</sup> 2010	-	-	-	-	-	-	-	-	Significant improvement
Ji et al., <sup>22</sup> 2014	146.2 ± 19.3	161.8 ± 16.8	37.4 ± 25.1	67.3 ± 21.8	142.8 ± 24.1	162.6 ± 18.3	L1 (buttock- T7)	T12 (buttock- T7)	Significant improvement

NOTE: Data are presented as mean ± standard deviation.

## Surgical Techniques

The biceps tendon was used for augmentation in both open and arthroscopic procedures. In 3 studies, the proximal insertion was left intact,<sup>16,17,22</sup> whereas in another 3 studies, the distal portion was left intact.<sup>19,20,22</sup> A tenodesis of the distal portion of the intra-articular part of the biceps tendon was performed in 4 studies,<sup>15,17,18,21</sup> and a free graft (cut at both ends) was used in 3 studies.<sup>15,18,21</sup> The tendon was weaved, was used as an onlay, was fixed in a longitudinal way, was first fixed to the cuff or first to the footprint, and was sometimes described as “attached tension-free.” In some studies the tendon was split longitudinally before being used.<sup>17,21</sup> Standard acromioplasty was performed in 3 studies,<sup>15,16,22</sup> and in 2 others, it was performed when indicated.<sup>16,20</sup> There was no mention of any intervention on the acromion in the remaining studies.

## Functional Outcome

In 7 of the 8 clinical studies, a functional outcome score was used, albeit without the use of a standard outcome score in any of the studies (Tables 4 and 5). The Constant-Murley score (CMS) was used in 4 studies<sup>17-20</sup>; the University of California, Los Angeles score was used in 3 studies.<sup>19,20,22</sup> The Simple Shoulder Test, American Shoulder and Elbow Surgeons score, and Japanese Orthopaedic Association shoulder score were each used in 1 study. Differences between scores before and after the intervention are presented in Table 4, and all studies using an outcome score showed significant improvement. One study noted an improvement but did not mention the outcome score. When measuring function, 6 studies showed a significant increase in the range of motion (Table 5). In 5 studies, patients reported a significant decrease in pain on a visual analog scale<sup>17,19-22</sup>; in the other 3, it was not noted.<sup>15,16,18</sup>

## Radiologic Outcome

A total of 112 magnetic resonance imaging (MRI) scans were performed in 5 studies (Table 6)<sup>18-22</sup>: 68 showed intact graft constructs (61%); 23 showed thinning, granulation tissue, or partial tears (21%); and 21 showed re-ruptured graft constructs (19%). Two studies reported the time between surgery and MRI as ranging from 12 to 51 months.

**Table 6,** Pain Score and MRI evaluation

Study	Cuff integrity	Timing of MRI
Neviaser, <sup>15</sup> 1971	–	–
Wolfgang, <sup>16</sup> 1974	–	–
Güven, <sup>17</sup> 2001	–	–
Pavlidis et al., <sup>18</sup> 2003	10 intact, 4 thinning, 1 re-rupture	Not noted
Rhee et al., <sup>19</sup> 2008	9 intact, 2 partial re-rupture, 3 re-rupture	Not noted
Cho et al., <sup>20</sup> 2009	14 intact, 10 re-rupture	Mean, 15 mo
Sano et al., <sup>21</sup> 2010	13 intact, 10 thinning, 1 re-rupture	Not noted
Ji et al., <sup>22</sup> 2014	22 intact, 7 partial re-rupture, 6 re-rupture	Range, 12-51 mo

MRI, magnetic resonance imaging

## DISCUSSION

The results of using biceps tendon autografts in reconstruction of rotator cuff tears are comparable with those of studies using artificial grafts such as non-cross-linked human dermis scaffolds. Eight case series could be found, and the total number of patients was 170, with the mean age ranging from 55 to 64 years. The summary of the quality-analysis questions ranged from 38% to 86% as a percentage of the maximum attainable score; 6 studies were considered high quality and 2 were medium quality. Each study used a different technique, and both open and arthroscopic procedures were performed. All showed improvement in different functional scores, and the authors of the studies considered this improvement clinically relevant. As for the studies using the CMS, all scores improved by more than 10.4 points, which is considered a threshold for the minimal clinically important difference.<sup>26</sup> For the other outcome scores used, no minimal clinically important difference has been described, so any conclusions should be interpreted with caution. Of the 8 studies, 3 did not mention any effect on pain. In 5 studies follow-up was performed using MRI, showing 81% fully or partially intact cuffs. All proposed techniques are augmentations for supporting the biomechanical forces, and they seem less suitable for tissue bridging, this is in contrast to other graft techniques.

Different techniques have been proposed to improve the results of cuff repairs, such as the use of anchors for better bone fixation, in a single or double row, thereby theoretically offering better fixation and biomechanics. There has also been a focus on the biological processes of tendon healing by promoting intrinsic repair with stimulation of the ingrowth using BMPs, PRP, and other growth factors.<sup>4-6</sup> The use of BMPs in *in vivo* experiments has shown promising results, although a recent meta-analysis of the use of PRP after arthroscopic cuff repair showed no benefit.<sup>4-6</sup> Another technique, augmentation with synthetic or acellular human- or animal-based scaffolds, is based on principles of offering biological ingrowth of tenocytes and better biomechanics, although it does not always stimulate cell ingrowth and can be costly. Results are still inconsistent when compared with traditional cuff repair.<sup>7-9</sup> One study consisting of 16 patients with a massive rotator cuff tear size (>5 cm and/or 2 tendons involved) treated with a GraftJacket allograft (Wright Medical Technology, Arlington, TN) showed an improvement from 18.4 to 30.4 in the University of California, Los Angeles score and from 53.8 to 84.0 in the CMS after a mean follow-up period of 27 months.<sup>27</sup> This compares quite nicely with the scores of the different studies in our review (Table 4). In a randomized controlled trial using a GraftJacket allograft, MRI scans were obtained after 1 to 2 years' follow-up, showing 85% intact repairs in the augmented group and 40% in the non-augmented group.<sup>28</sup> It should be noted that with this scaffold, a larger gap can be bridged because it is available with dimensions of up to 4.7 cm. Superior capsule



reconstruction is another technique for the treatment of massive rotator cuff tears; it emphasizes covering the humeral head.<sup>29</sup> This is in contrast to the technique of using the BAG as a scaffold or bridge for cuff repair.

Series reporting on the use of a non-cross-linked scaffold made of porcine small intestinal submucosa (Restore, DePuy) showed a severe, sterile postoperative inflammatory reaction in 20% to 30% of patients. One of these trials was aborted for this reason.<sup>30</sup> A study by Encalada-Diaz et al.<sup>31</sup> evaluated the use of the synthetic scaffold Biomerix RCR Patch (polycarbonate polyurethane) as an augmentation device in 10 patients and reported a 10% failure rate on MRI. Because the scaffold was used in small-to medium-sized tears in their study, it is not comparable. Use of the BAG has also been described for revision rotator cuff tears, showing good results in 10 patients.<sup>32</sup>

The incidence of rotator cuff tears increases with age. Up to 62% of patients aged 80 years or older show symptomatic or nonsymptomatic tears.<sup>33</sup> Patients with symptomatic rotator cuff tears present with pain, decreased range of motion, and limitations in daily life. After failed conservative therapy, surgical repair is an option.<sup>1</sup> Rotator cuff tears can occur as part of degenerative cuff disease in middle-aged or older patients and as a result of lower tendon quality.<sup>33</sup> In some patients with rotator cuff tears, the biceps tendon is also degenerated; hence not all patients are eligible for the technique. Use of a hamstring autograft (semitendinosus and/or gracilis muscle) can be an option.<sup>34</sup>

This surgical technique of using the biceps tendon as augmentation can be an option for patients with shoulder dysfunction and pain resulting from a massive rotator cuff tear when other surgical repairs do not seem suitable. The technique uses no artificial augmentation, so it is comparatively less costly than other techniques; however, the results can be influenced by the different techniques that are used. Some studies left the proximal or distal portion intact, whereas others used it as a free graft. Several of the studies in this review used the BAG for treatment of massive cuff tears, which are defined as 2- or 3-tendon tears of the cuff that can be challenging to treat.<sup>35</sup> These tears can be retracted and cannot be mobilized to be reconstructed up to the original footprint. A muscle transfer such as latissimus dorsi muscle transfer can be an option, although the results are unpredictable; a more anatomic repair is preferred.<sup>36</sup>

It is recommended that medium- and long-term results be collected in studies with a prospective design. Studies should also be powered sufficiently to assess the relevance of any improvement in clinical results. Patient-reported outcome scores can be of added value in studies such as these, given that the scores in this review are mainly functional. It would also be interesting to have some histologic samples to see if the tenocytes really incorporate or scar tissue remains. Although the studies have varying levels of

evidence, the clinical and radiologic results are comparable with the literature on other scaffolds.

### Limitations

This study should be interpreted cautiously because rotator cuff tears of different sizes are included and this may influence outcomes. In addition, the biceps tendon is known for being a source of pain; therefore, a biceps tenotomy itself may already lead to pain reduction.<sup>37</sup> Another limitation of this systematic review is the heterogeneity of the study population. Because of the type of study, only a general tool to assess the quality and, consequently, the risk of bias could be used. Publication bias may also be present. Finally, the statements about the BAG are based on case series, that is, studies without control groups. No recommendations could be provided based on the current evidence.

## CONCLUSIONS

It can be concluded that use of a BAG is an option for augmentation in massive rotator cuff tears, although no definitive recommendations can be given. This is based on Level IV medium- and high-quality studies.

## REFERENCES

1. Lambers Heerspink FO, van Raay JJ, Koorevaar RC, et al. Comparing surgical repair with conservative treatment for degenerative rotator cuff tears: A randomized controlled trial. *J Shoulder Elbow Surg* 2015;24:1274-1281.
2. Kukkonen J, Joukainen A, Lehtinen J, et al. Treatment of nontraumatic rotator cuff tears: A randomized controlled trial with two years of clinical and imaging follow-up. *J Bone Joint Surg Am* 2015;97:1729-1737.
3. Cofield RH, Parvizi J, Hoffmeyer PJ, Lanzer WL, Ilstrup DM, Rowland CM. Surgical repair of chronic rotator cuff tears: A prospective long-term study. *J Bone Joint Surg Am* 2001;83:71-77.
4. Kabuto Y, Morihara T, Sukenari T, et al. Stimulation of rotator cuff repair by sustained release of bone morphogenetic protein-7 using a gelatin hydrogel sheet. *Tissue Eng* 2015;21:2025-2033.
5. Li X, Xu CP, Hou YL, Song JQ, Cui Z, Yu B. Are platelet concentrates an ideal biomaterial for arthroscopic rotator cuff repair? A meta-analysis of randomized controlled trials. *Arthroscopy* 2014;30:1483-1490.
6. Wang A, McCann P, Colliver J, et al. Do postoperative platelet-rich plasma injections accelerate early tendon healing and functional recovery after arthroscopic supraspinatus repair? A randomized controlled trial. *Am J Sports Med* 2015;43:1430-1437.
7. Chaudhury S, Holland C, Thompson MS, Vollrath F, Carr AJ. Tensile and shear mechanical properties of rotator cuff repair patches. *J Shoulder Elbow Surg* 2012;21: 1168-1176.
8. Gillespie RJ, Knapik DM, Akkus O. Biologic and synthetic grafts in the reconstruction of large to massive rotator cuff tears. *J Am Acad Orthop Surg* 2016;24:823-828.
9. Ricchetti ET, Aurora A, Iannotti JP, Derwin KA. Scaffold devices for rotator cuff repair. *J Shoulder Elbow Surg* 2012;21:251-265.
10. Pietschmann MF, Wagenhauser MU, Gulecyuz MF, Ficklscherer A, Jansson V, Muller PE. The long head of the biceps tendon is a suitable cell source for tendon tissue regeneration. *Arch Med Sci* 2014;10:587-596.
11. Moher D, Liberati A, Tetzlaff J, Altman DG, PRISMA Group. Preferred reporting items for systematic reviews and meta-analyses: The PRISMA statement. *PLoS Med* 2009;6:e1000097.
12. Higgins JP, Green S. *Cochrane handbook for systematic reviews of interventions*. Hoboken, NJ: John Wiley & Sons, 2011.
13. Law MC, MacDermid J. *Evidence-based rehabilitation: A guide to practice*. Thorofare, NJ: Slack, 2002.
14. Peters JA, Zwerver J, Diercks RL, Elferink-Gemser MT, van den Akker-Scheek I. Preventive interventions for tendinopathy: A systematic review. *J Sci Med Sport* 2016;19:205-211.
15. Neviasser JS. Ruptures of the rotator cuff of the shoulder. New concepts in the diagnosis and operative treatment of chronic ruptures. *Arch Surg* 1971;102:483-485.
16. Wolfgang GL. Surgical repair of tears of the rotator cuff of the shoulder. Factors influencing the result. *J Bone Joint Surg Am* 1974;56:14-26.
17. Guven O, Bezer M, Guven Z, Gokkus K, Tetik C. Surgical technique and functional results of irreparable cuff tears reconstructed with the long head of the biceps tendon. *Bull Hosp Jt Dis* 2001;60:13-17.
18. Pavlidis T, Ganten M, Lehner B, Dux M, Loew M. Tenoplasty of the long head of the biceps in massive rotator cuff tear. *Z Orthop Ihre Grenzgeb* 2003;141:177-181 [in German].
19. Rhee YG, Cho NS, Lim CT, Yi JW, Vishvanathan T. Bridging the gap in immobile massive rotator cuff tears: Augmentation using the tenotomized biceps. *Am J Sports Med* 2008;36:1511-1518.
20. Cho NS, Yi JW, Rhee YG. Arthroscopic biceps augmentation for avoiding undue tension in repair of massive rotator cuff tears. *Arthroscopy* 2009;25:183-191.

21. Sano H, Mineta M, Kita A, Itoi E. Tendon patch grafting using the long head of the biceps for irreparable massive rotator cuff tears. *J Orthop Sci* 2010;15:310-316.
22. Ji JH, Shafi M, Jeong JJ, Park SE. Arthroscopic repair of large and massive rotator cuff tears using the biceps-incorporating technique: Mid-term clinical and anatomical results. *Eur J Orthop Surg Traumatol* 2014;24:1367-1374.
23. van Tulder M, Furlan A, Bombardier C, Bouter L, Editorial Board of the Cochrane Collaboration Back Review Group. Updated method guidelines for systematic reviews in the Cochrane Collaboration Back Review Group. *Spine (Phila Pa 1976)* 2003;28:1290-1299.
24. Richards DP, Burkhart SS. Margin convergence of the posterior rotator cuff to the biceps tendon. *Arthroscopy* 2004;20:771-775.
25. Obma PR. Free biceps tendon autograft to augment arthroscopic rotator cuff repair. *Arthrosc Tech* 2013;2:e441-e445.
26. Kukkonen J, Kauko T, Vahlberg T, Joukainen A, Äärimaa V. Investigating minimal clinically important difference for Constant score in patients undergoing rotator cuff surgery. *J Shoulder Elbow Surg* 2013;22: 1650-1655.
27. Bond JL, Dopirak RM, Higgins J, Burns J, Snyder SJ. Arthroscopic replacement of massive, irreparable rotator cuff tears using a GraftJacket allograft: Technique and preliminary results. *Arthroscopy* 2008;24:403-409.
28. Barber FA, Burns JP, Deutsch A, Labbe MR, Litchfield RB. A prospective, randomized evaluation of acellular human dermal matrix augmentation for arthroscopic rotator cuff repair. *Arthroscopy* 2012;28:8-15.
29. Mihata T, Lee TQ, Watanabe C, et al. Clinical results of arthroscopic superior capsule reconstruction for irreparable rotator cuff tears. *Arthroscopy* 2013;29:459-470.
30. Iannotti JP, Codsí MJ, Kwon YW, Derwin K, Ciccone J, Brems JJ. Porcine small intestine submucosa augmentation of surgical repair of chronic two-tendon rotator cuff tears. A randomized, controlled trial. *J Bone Joint Surg Am* 2006;88:1238-1244.
31. Encalada-Díaz I, Cole BJ, Macgillivray JD, et al. Rotator cuff repair augmentation using a novel polycarbonate polyurethane patch: Preliminary results at 12 months' follow-up. *J Shoulder Elbow Surg* 2011;20:788-794.
32. Skoff HD. Revision rotator cuff reconstruction for large tears with retraction: A novel technique using autogenous tendon and autologous marrow. *Am J Orthop (Belle Mead NJ)* 2015;44:326-331.
33. Teunis T, Lubberts B, Reilly BT, Ring D. A systematic review and pooled analysis of the prevalence of rotator cuff disease with increasing age. *J Shoulder Elbow Surg* 2014;23:1913-1921.
34. Gigante A, Bottegoni C, Milano G, Riccio M, Dei Giudici L. Semitendinosus and gracilis free muscle-tendon graft for repair of massive rotator cuff tears: Surgical technique. *Joints* 2016;4:189-192.
35. Thorsness R, Romeo A. Massive rotator cuff tears: Trends in surgical management. *Orthopedics* 2016;39:145-151.
36. Gerber C, Rahm SA, Catanzaro S, Farshad M, Moor BK. Latissimus dorsi tendon transfer for treatment of irreparable posterosuperior rotator cuff tears: Long-term results at a minimum follow-up of ten years. *J Bone Joint Surg Am* 2013;95:1920-1926.
37. Kang JR, Sin AT, Cheung EV. Treatment of massive irreparable rotator cuff tears: A cost-effectiveness analysis. *Orthopedics* 2016;29:1-12.





**Using the long head of biceps tendon autograft as an anatomical reconstruction of the rotator cable: an arthroscopic technique for patients with massive rotator cuff tears**

Egbert J.D. Veen  
Cornelis T. Koorevaar  
Ronald L. Diercks

*Arthroscopy techniques*  
2018, 7(7), e699-e703

## ABSTRACT

The treatment of massive rotator cuff tears (MRCT) is challenging. Insufficient tissue quality, size, and retraction of the cuff often lead to failures of repair. Different techniques like direct repair, partial repair, and graft applications have been developed, but results are not yet predictable. In this arthroscopic technique the objective is not to reconstruct the rotator cuff as a tissue layer but to restore the biomechanical function of the rotator cable with an autograft of the long head of the biceps tendon. After glenohumeral inspection, the long head of the biceps tendon is harvested and the retracted cuff is released and, if possible, closed partially side-to-side. The biceps graft is positioned from the posterior aspect of the greater tubercle to the superior part of the lesser tubercle and fixed with 2 biotenodesis anchors. Finally, the cuff remnants are securely sutured to the biceps graft with standard cuff repair sutures. This arthroscopic technique has several advantages because the biceps autograft is easily harvested, autologous, and rich in collagen. Previous studies show use of the biceps tendon differently for reconstruction of the rotator cuff, with promising results. Future studies are needed to evaluate clinical outcomes.



## INTRODUCTION

Massive rotator cuff tears (MRCTs) often cause impairment, pain, and loss of function. These tears are defined as 2 or more tendons involved and/or more than 5 cm retraction.<sup>1</sup> As a result of the retraction it is not always possible to fix the rotator cuff to the original footprint at the greater tubercle. To overcome these difficulties, several techniques have been developed with variable outcomes. These include xenograft, synthetic patches, and allografts. All are costly and do not stimulate ingrowth.<sup>2</sup> Graft reactions are also seen. Other extensive surgeries like latissimus dorsi or teres minor muscle transfer are described but have limited indications.<sup>3</sup>

When treating rotator cuff tears, a tenotomy or tenodesis of the long head of the biceps is often part of the surgical procedure. In some studies the intra-articular portion is used as a graft for bridging the gap in MRCTs. In those techniques, the tendon is longitudinally incised and used to fill the gap or as augmentation.<sup>4</sup> What we propose is using the long head of the biceps tendon to restore the rotator cable. The rotator cable, a thickening in the rotator cuff, was reported by Burkhart et al.,<sup>5</sup> who described a structure in the superior articular capsule that acts like a loaded suspension bridge cable and serves as a primary load-bearing structure between the rotator cuff and the humerus. This function has been clearly identified in biomechanical cadaveric studies.<sup>6,7</sup>

We developed a technique to treat MRCT by reconstructing the rotator cable with a long head of the biceps tendon autograft.

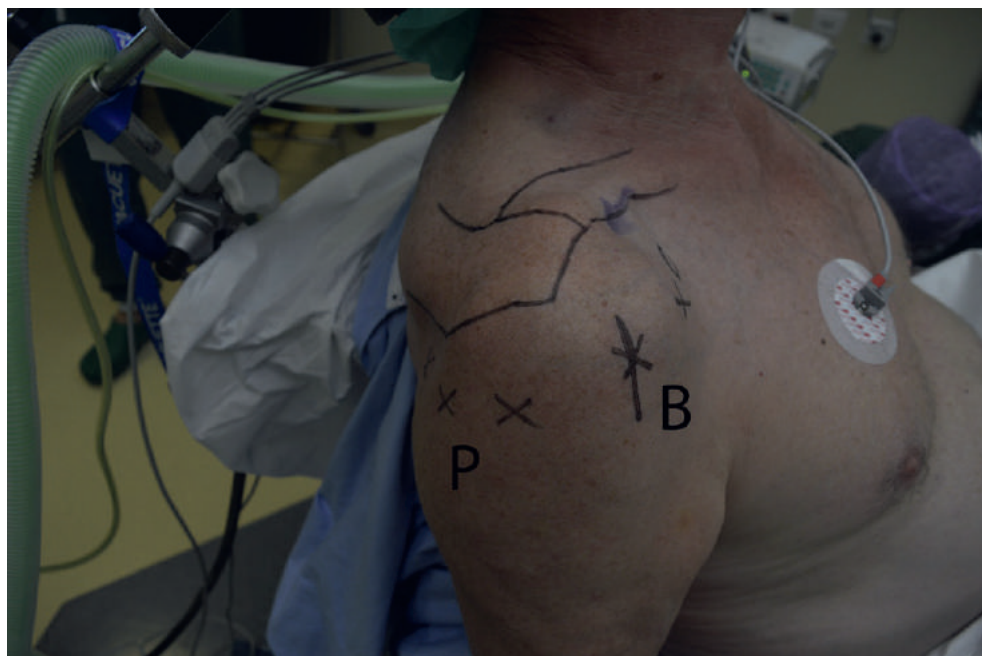
## SURGICAL TECHNIQUE

### Indications

This technique is indicated for patients with an MRCT and failure after conservative treatment with injections and/or physiotherapy for >3 months. Patients should not have any previous surgery on the affected shoulder or signs of symptomatic acromioclavicular/glenohumeral osteoarthritis (Table 1).

**Table 1.** Inclusion and Exclusion Criteria for Using Biceps Autograft Technique

Inclusion Criteria	Exclusion Criteria
Massive rotator cuff tear (2-3 tendons)	Previous surgery on the shoulder
Conservative treatment failed	Symptomatic acromioclavicular osteoarthritis
Age <70 years	Glenohumeral osteoarthritis
Retraction (Patte stage 3 or lower)	Rheumatoid arthritis
	Degenerated biceps tendon
	Fatty infiltration (Goutallier stage 3 or higher)
	Primary cuff repair feasible at surge



**Fig 1.** Patient in beach chair position seen from lateral side with anatomy and portals marked on the right shoulder. (B, biceps graft harvest incision; P, posterior side.)

## Preparation

Patients are operated in the beach chair position with an interscalene block of the brachial plexus and general anesthesia. The anatomical landmarks and position of the portals are marked (Fig 1). After disinfection with chlorhexidine and standard sterile draping, the arthroscopic procedure is performed with a 30 degrees arthroscope.

## Routine Intra-articular Procedure

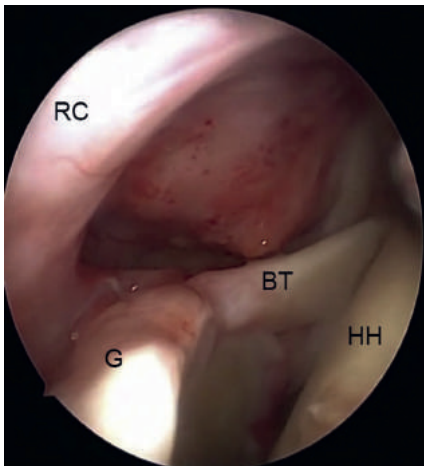
The standard procedure starts by introducing the scope through the posterior portal. The anterior portal is created under direct vision. The quality of the cartilage is recorded, and the different tendons of the cuff are inspected (Fig 2). A primary cuff repair is performed, if possible.

## Long Head of the Biceps Tendon Tenotomy

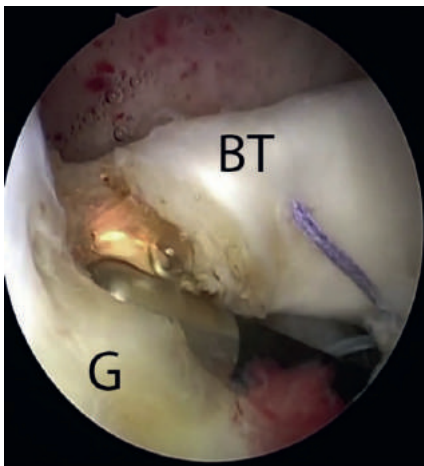
After confirming the diagnosis of MRCT, the intra-articular portion of the biceps is tenotomized just distal to the insertion on the superior labrum (Fig 3). If the subscapularis is ruptured, a primary repair to the lesser tubercle with suture anchor(s) is performed.

## Harvesting the Long Head of the Biceps Tendon


A small anterolateral incision is made at the bicipital sulcus. The long head of the biceps tendon is released, and the proximal portion is pulled out. While tensioning the proximal biceps tendon, the distal part can be mobilized and cut with scissors approximately 2 cm into the muscle. The tendon can now be prepared in a similar fashion as the hamstring tendons in anterior cruciate ligament reconstruction (Fig 4). Generally, a minimal length of 70 mm is harvested in all, with a diameter of approximately 6 mm.



**Fig 2.** Intra-articular inspection seen from posterior portal of a right shoulder. (BT, biceps tendon; G, glenoid; HH, humeral head; RC, rotator cuff.)



**Fig 3.** Tenotomy of biceps tendon close to insertion on the glenoid. Seen from a posterior portal of a right shoulder. (BT, biceps tendon; G, glenoid.)



**Fig 4.** Preparation of the biceps autograft with a length of 70 mm and marked at both ends, which will be inserted with the anchors. (BAG, biceps auto graft.)

### Cuff Preparation and Mobilization

The subacromial space is inspected, and a bursectomy is performed through a lateral portal to create a clear view of the remnants of the rotator cuff. Size and level of retraction are identified. A supporting suture is passed through the supraspinatus tendon and pulled laterally to see whether mobilizing close to the footprint is possible (Fig 5). An extensive release of the cuff is performed subacromially and between the cuff and the superior labrum with close attention to the suprascapular nerve, which passes approximately 10 mm medial to the glenoid rim.

### Partial Cuff Repair

In case of an L-shaped or reverse L-shaped rupture, one or more side-to-side sutures with nonabsorbable polyethylene sutures (Ultrabraid, Smith and Nephew, Andover, MA) is placed to achieve a partial cuff repair.

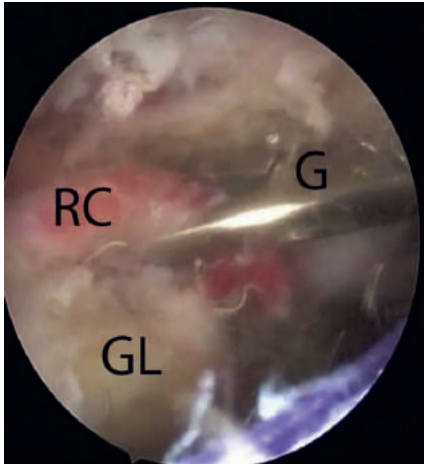
### Biceps Graft Preparation

After debridement of the footprint, a suture tensioned over the humeral head and marked at the planned locations of the tenodesis screws is used to measure the length of the biceps graft. (Fig 6). It usually measures around 30 mm. The tendon is prepared and marked, with 20 mm of tendon left on each side to be inserted into the humeral bone with the biotenodesis screws. In most cases, a tendon graft of 70 mm is needed (Fig 7). Swivelock tenodesis biocomposite anchors (7 x 19.1 mm) are used (Arthrex).

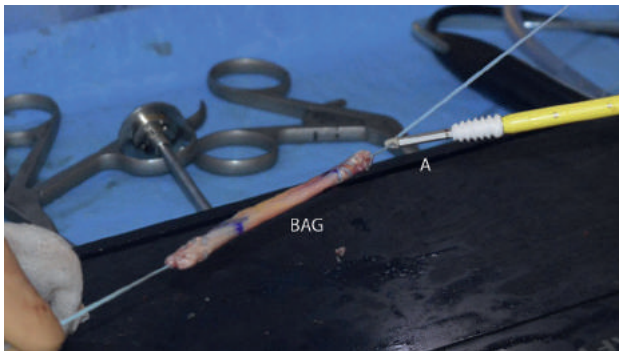
### Biceps Graft Fixation

An additional posterolateral portal is made to drill a hole for the posterior screw with a diameter equal to the tendon, approximately in the middle of the footprint of the infraspinatus on the greater tubercle. With the biceps autograft under tension, this posterior screw is tightly inserted until the premarked portion of the biceps tendon (20 mm; Fig 8). After positioning of the graft, a drill hole is made in the biceptal groove

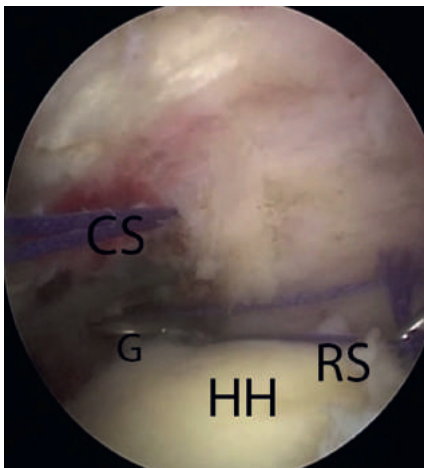
at the superior part of the lesser tubercle. The anterior tenodesis screw is placed while maintaining adequate traction on the graft. This results in a tensioned biceps autograft in posterior-to-anterior direction over the humeral head. We emphasize the tightening of the graft to prevent medialization during the cuff repair.



**Fig 5.** Mobilizing of the rotator cuff seen from a posterior portal of a right shoulder and the grasper inserted from a lateral portal. (G, grasper; GL, glenoid; RC, rotator cuff.)



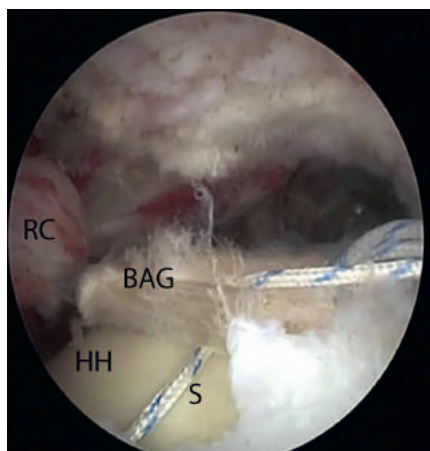
**Fig 6.** Measurement of the needed length of the biceps graft with help of a suture. Seen from a posterior portal. (CS, cuff suture; G, grasper; HH, humeral head; RS, ruler suture.)



**Fig 7.** Final preparation of the biceps autograft with the anchor attached to the graft seen from a posterior portal of a right shoulder. (A, Swivelock tenodesis biocomposite anchor (7 x 19.1 mm; Arthrex); BAG, biceps autograft.)

### Final Rotator Cuff Repair to Rotator Cable

The final step is the actual cuff repair. Nonabsorbable polyethylene sutures (Ultrabraid, Smith and Nephew) are used. The sutures are passed transversely around and through the biceps tendon autograft (Fig 9). The medial part of the sutures is passed through the infraspinatus and supraspinatus tendons with a suture device (Scorpion, Arthrex). An average of 5 sutures are needed in order to bring the rotator cuff to the biceps tendon autograft. The whole construct is tested for stability. The biceps tendon autograft is not fixed to the original footprint of the rotator cuff. Wounds are closed transcutaneously, and the arm is put in a shoulder sling immobilizer.



### Rehabilitation

The shoulder is immobilized for 6 weeks, during which passive movements were allowed under guidance of a physiotherapist. After 6 weeks, active training is started. Patients are seen 6 weeks and 3, 6, and 12 months postoperatively.

**Table 2.** Pearls and Pitfalls for Reconstruction of the Rotator Cable in Massive Rotator Cuff Tears

#### Pearls and Pitfalls

- Harvest a biceps tendon of at least 70 mm
- Harvest the biceps tendon as distally as possible
- Use a suture as a measurement tool
- Extensive release of the rotator cuff
- Secure the biceps tendon tight over the humeral head
- Use at least 4 sutures to secure the cuff to the reconstructed rotator cable

**Table 3.** Possible Advantages and Disadvantages of Using Biceps Autograft for Reconstruction Rotator Cable in Massive Rotator Cuff Tears

Advantages	Disadvantages
Anatomical reconstruction of the rotator cable	No fixation cuff to footprint
Biceps tendon is rich in collagen	Possible degenerative biceps tendon
Easy to harvest	High tension on cuff and tendon graft
Use of an autograft (biceps tendon)	Not possible in end-stage fatty infiltration
Arthroscopic technique	Not possible in end-stage retraction
No graft reactions	Extensive arthroscopic technique
Fixation of cuff to reconstructed rotator cable and not to footprint	
May prevent cuff arthropathy	

## DISCUSSION

Video 1 demonstrates an arthroscopic technique for functional reconstruction of massive, symptomatic rotator cuff tears by recreating the rotator cable with a biceps tendon autograft. The pearls and pitfalls are shown in Table 2. Using the biceps tendon has several advantages.

As noted before, with this technique the natural rotator cable is restored using an autograft, avoiding graft reactions. Previous studies show that the biceps is rich in collagen, even when tendinopathy is present.<sup>8</sup> In all patients treated with this technique, the cuff tendons could be approximated to the graft after extensive mobilization with a tissue ablation device. The medialization of the biceps graft under tension may contribute to successful attachment of the cuff. This technique may also prevent proximalization of the humeral head in order to delay development of cuff arthropathy.

A possible risk is insufficient ingrowth into the graft. Tenocytes of the biceps tendon are pointed in a different direction than the rotator cuff tendons, but this is also seen in the natural rotator cable. Care should be taken for the suprascapular nerve when mobilizing the cuff past the glenoid rim; as mentioned before, this nerve can be as close as 10 mm. The fatty infiltration and retraction are part of the MRCT, yet they can make the surgery more challenging. Also, the unavoidable tension on the construct may contribute to a delayed healing process. When tensioned inadequately the forces of the cuff may result in insufficient leverage. One other limitation is the absence of the biceps tendon inside the glenohumeral joint if the biceps tendon is ruptured spontaneously or has severe tendinosis. In those cases a hamstring graft can be used. The advantages and disadvantages are shown in Table 3.

Reconstruction of the rotator cable using a biceps tendon autograft can be an option for the treatment of MRCTs. After harvesting, the biceps tendon is positioned as a cable using tenodesis screws and the remains of the cuff are secured to the graft. The graft is easy to harvest, and a more biomechanical reconstruction is created.

## **ACKNOWLEDGMENT**

The authors thank Tom Tieman for editing the video.



## REFERENCES

1. Lädermann A, Denard PJ, Collin P. Massive rotator cuff tears: Definition and treatment. *Int Orthop* 2015;39: 2403-2414.
2. Deprés-Tremblay G, Chevrier A, Snow M, Hurtig MB, Rodeo S, Buschmann MD. Rotator cuff repair: A review of surgical techniques, animal models, and new technologies under development. *J Shoulder Elbow Surg* 2016;25:2078-2085.
3. Gerber C, Maquieira G, Espinosa N. Latissimus dorsi transfer for the treatment of irreparable rotator cuff tears. *JBJS* 2006;88:113-120.
4. Rhee YG, Cho NS, Lim CT, Yi JW, Vishvanathan T. Bridging the gap in immobile massive rotator cuff tears: Augmentation using the tenotomized biceps. *Am J Sports Med* 2008;36:1511-1518.
5. Burkhart SS, Esch JC, Jolson RS. The rotator crescents and rotator cable: An anatomic description of the shoulder's "suspension bridge". *Arthroscopy* 1993;9:611-616.
6. Mesiha MM, Derwin KA, Sibole SC, Erdemir A, McCarron JA. The biomechanical relevance of anterior rotator cuff cable tears in a cadaveric shoulder model. *J Bone Joint Surg Am* 2013;95:1817-1824.
7. Rahu M, Kolts I, Põldoja E, Kask K. Rotator cuff tendon connections with the rotator cable. *Knee Surg Sports Traumatol Arthrosc* 2017;25:2047-2050.
8. Mazzocca AD, McCarthy MB, Ledgard FA, et al. Histomorphologic changes of the long head of the biceps tendon in common shoulder pathologies. *Arthroscopy* 2013;29:972-981.



**The results of using a tendon autograft as a new rotator cable for patients with a massive rotator cuff tear: a technical note and comparative outcome analysis**

Egbert J.D. Veen  
Ronald L. Diercks  
Ellie B.M. Landman  
Cornelis T. Koorevaar

*Journal of Orthopaedic Surgery and Research*  
2017, 15(1), 1-7

## ABSTRACT

### Background

Several surgical reconstructive options are available to treat massive rotator cuff tears (MRCTs). The rotator cable has an important function and we evaluated the clinical result after arthroscopic reconstruction of the rotator cable with an autograft tendon.

### Methods

A prospective pilot study was performed with inclusion of four patients, average age of 64 years, with an irreparable MRCT. The patients underwent an arthroscopic reconstruction of the rotator cable with the use of the long head of biceps tendon autograft, except for one which was reconstructed with a hamstring tendon. Pre- and postsurgically, the Constant-Murley Score (CMS), Western Ontario Rotator Cuff Index (WORC), Simple Shoulder Test (SST), visual analog scale (VAS) scores, and an MRI was performed. Clinical results of the study group were compared with clinical results of comparable cohort of patients with a MRCT, treated non-operatively with physiotherapy.

### Results

The CMS score increased after surgery in three of the four patients. The improvement of CMS score was comparable to the improvement of the CMS score encountered in a comparable cohort. The MRI at 12 months follow-up showed that the reconstructed rotator cable was disintegrated in all patients and the rotator cuff was detached and retracted.

### Conclusions

In our pilot study, arthroscopic reconstruction of the rotator cable using a tendon autograft failed over time and showed no clinical benefit in comparison to the non-operative treatment with physiotherapy.

### Trial registration

The regional Medical Ethical Committee (Zwolle) gave approval at 14th of October 2016 and assigned no. 16.06100.

### Keywords

Biceps tendon, Massive rotator cuff tear, Autograft, Arthroscopy

## INTRODUCTION

Massive rotator cuff tears (MRCTs) are defined as cuff tears involving two or more cuff tendons or a retraction of  $\geq 5$  cm [1]. Patients frequently present with pain and loss of function (pseudoparalysis), sometimes after minimal trauma. A MRCT can have a huge impact on daily life and eventually could lead to a cuff arthropathy. Variable success rates are seen after primary cuff repair in small-to-medium-sized tears with retear rates between 14 and 25% [2]. If the repair is successful and the cuff has healed after surgery, patients have a better outcome compared with patients after conservative or failed surgical therapy [3, 4]. MRCT defects cannot be easily closed, and there is a rate of retears reaching up to 94% [5, 6]. Several surgical reconstructive options for MRCTs are available, each with its own reported advantages and complications [7]. Patches and grafts are expensive and can lead to rejection. Another technique is superior capsular reconstruction to treat these lesions [8]. Initial results for reconstruction of the superior capsule seem promising, although long-term results are awaited. Reversed shoulder arthroplasties and tendon transfers are alternative options, yet these are major surgeries with considerable morbidity [9].

A tenotomy or tenodesis of the long head of the biceps tendon is often performed as part of rotator cuff surgery. This offers the possibility of using the biceps tendon as a graft. Different studies used this tendon as a free graft or leaving the distal or proximal attachment intact, reporting significant improvement of function [10]. In the native shoulder, the rotator cable is a thickening in the rotator cuff that serves as a primary load-bearing structure between the rotator cuff and the humerus and functions as a tension bridge. Recent studies show the clinical and biomechanical importance of this structure [11, 12].

We developed a technique to treat MRCTs by reconstructing the rotator cable with a long head of biceps tendon autograft [13]. But a hamstring tendon is also suitable. This technique represents a reconstruction with several advantages: use of an autograft, ease of harvesting, no graft reactions, fixation of cuff to reconstructed rotator cable instead of footprint, and potential prevention of cuff arthropathy.

The aim of this study is to evaluate the clinical and radiological result after arthroscopic reconstruction of the rotator cuff cable with an autograft tendon in patients with irreparable massive rotator cuff tears.

## METHODS

### Indications

A prospective pilot study was conducted between February and December 2016. Patients aged 50 or older diagnosed with an irreparable MRCT (2–3 tendon tears, Patte stage 3 retraction), based on MRI, were included [14]. At physical examination, all had impaired abduction and decreased strength of the infraspinatus and supraspinatus muscles. All had undergone conservative treatment of at least 3 months consisting of physiotherapy and/or subacromial injections, without the expected effect. Exclusion criteria were as follows: symptomatic glenohumeral or acromioclavicular osteoarthritis, rheumatoid arthritis, previous surgery on the same shoulder or arm, and cognitive or linguistic issues. After 1 year of inclusion, the clinical results of this new operative technique were evaluated. Four patients were included in this year. The local institutional review board approved this study (no. 16.06100), and all patients gave informed consent. The study was done according to the ethical standards of the 1964 Helsinki Declaration and its later amendments.

Primary outcome was the Constant-Murley Score (CMS). We looked secondarily at the Simple Shoulder Test (SST) [15], Western Ontario Rotator Cuff Index (WORC) [16], and visual analog scale (VAS) [17] on pain, disability, and patient satisfaction. Scores were taken preoperatively at 3, 6, and 12 months.

Prior to surgery and 12 months postoperatively, an MRI scan was performed and the rotator cuff retraction and fatty infiltration were graded with Patte and Fuchs scores [14, 18]. Extension of the tear and number of torn tendons were also noted. Evaluation was done by an experienced musculoskeletal radiologist.

The results were compared with a cohort of patients with a MRCT, Patte stage 3, treated non-operatively with physiotherapy. These patients were selected from a previous RCT performed at our institution, comparing surgical rotator cuff repair with conservative treatment for degenerative rotator cuff tears [3]. The conservative protocol has been described previously, and scores were collected with the same interval during 12 months [3]. From the patients treated non-operatively with physiotherapy, eight patients with a MRCT had a Patte stage 3 and were included; in five patients, all follow-up data were available and used as a comparable cohort.

### Surgical procedure

This technique was first tested on cadavers to assess feasibility and detect any pitfalls. All surgeries were performed by one shoulder surgeon (CK). The surgical technique was extensively described in a previous report [13].

Patients were operated in the beach chair position after an interscalene block of the brachial plexus and general anesthesia. The standard procedure started by introducing the scope through the posterior portal. After confirming the diagnosis of MRCT, the intra-articular portion of the biceps was tenotomized just distally of the insertion on the superior labrum. Next, the tendon was harvested through a small anterolateral incision at the bicipital sulcus. In case this tendon was degenerated, a hamstring autograft was used.

### **Cuff preparation and mobilization**

The subacromial space was inspected, and a bursectomy was performed through a lateral portal to create a clear view of the remnants of the rotator cuff. An extensive release of the cuff was performed subacromially and between the cuff and the superior labrum with close attention to the suprascapular nerve.

### **Biceps graft fixation**

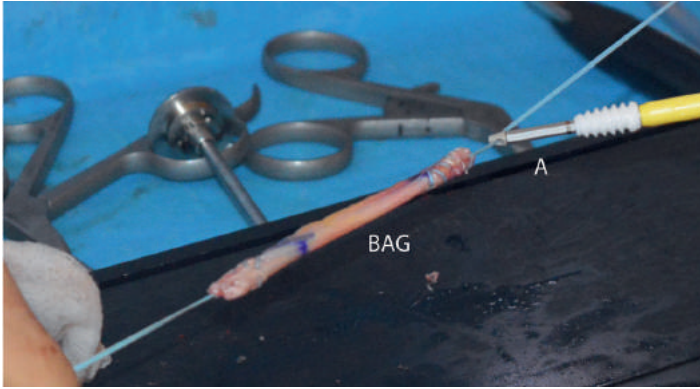
The tendon was prepared and marked, with 20 mm tendon left on each side to be inserted into the humeral bone with biotendosis screws (tenodesis biocomposite anchors, 7 × 19.1 mm) (Fig. 1). An additional posterolateral portal was made to drill a hole for the posterior screw with a diameter equal to the tendon, approximately in the middle of the footprint of the infraspinatus on the greater tubercle. With the biceps autograft under tension, this posterior screw was tightly inserted until the pre-marked portion of the biceps tendon (Fig. 2). After positioning of the graft, a drill hole was made in the bicipital groove at the superior part of the lesser tubercle.

### **Final rotator cuff repair to rotator cable**

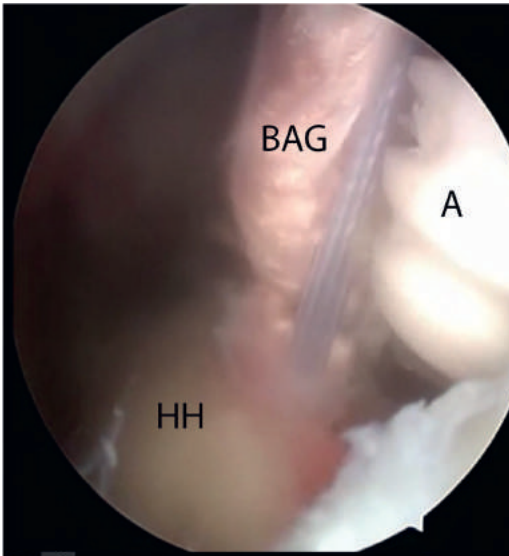
The final step was the actual cuff repair. The sutures were passed transversely around and through the biceps tendon autograft (Fig. 3). The medial part of the sutures was passed through the infraspinatus and supraspinatus tendons with a suture-passing device. An average of five sutures were needed in order to bring the rotator cuff to the tendon autograft.

### **Postoperative protocol**

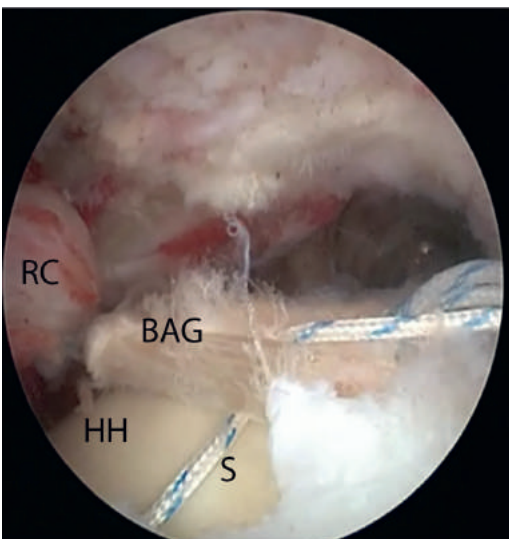
The shoulder was immobilized for 6 weeks, during which passive movements were allowed under the guidance of a physiotherapist. Afterwards, further guided active mobilization was started.



**Fig. 1.** Final preparation of the biceps autograft with the anchor attached to the graft. BAG: biceps autograft, a: tenodesis biocomposite anchor (7 mm x 19.1 mm)



**Fig. 3.** Attaching the cuff to the new reconstructed rotator cable using sutures. Seen from a posterior portal. RC: rotator cuff, HH: humeral head, BAG: biceps autograft, S: suture



**Fig. 2.** Insertion of anchor with biceps autograft attached into the humeral head after drilling. Seen from a posterior portal. HH: humeral head, BAG: biceps autograft, A: anchor



## Statistical analysis

Patient characteristics are expressed descriptively. The SPSS statistical software (version 20.0; IBM, Armonk, NY, USA) was used for data compilation and statistical analyses. Only descriptive statistics were considered suitable considering the number of patients in each group. Because of the pilot study design, a sample size calculation was not feasible.

## RESULTS

A total of four patients were included in this study. Patient characteristics are depicted in Table 1. Mean age of the study population was 64 years (61–67 years), all with their dominant side affected, and one was a smoker. In all patients, a massive cuff tear of the supraspinatus and infraspinatus tendon was present with a Patte stage 3 retraction; in one patient, a partial subscapularis tendon tear was found and repaired. Fatty infiltration on the postoperative MRI scan differed between Fuchs stages 2 to 3 on the preoperative MRI. One patient discontinued the study 9 months after surgery because of lack of postsurgical improvement, and a reversed shoulder prosthesis was inserted. The final scores of this patient were considered as an endpoint.

For comparison, a similar group of patients who were treated conservatively was selected. This comparable cohort consisted of five patients, mean age was 65 years (57–72 years), and more women were present in this group. All patients had a massive cuff tear of the supraspinatus and infraspinatus tendon with a Patte stage 3 retraction; in one patient only, the supraspinatus was torn and was treated using physiotherapy.

Table 2 shows the clinical outcome of the study group after surgery and the group treated with physiotherapy. Total CMS score increased significantly after surgery in three of the four patients, with a mean improvement of 26.4 points after 12 months ( $p = 0.023$ ) (Fig. 4). The WORC index, depicted as a percentage of a normal score, showed a mean improvement of 5 points ( $p = 0.191$ ). SST, VAS pain, VAS disability, and VAS satisfaction scores also improved in these patients. All except for patient 4 showed improvement on the scores. In all patients, an MRI was performed 12 months after surgery. In all patients, the reconstructed rotator cable had disintegrated and the rotator cuff was detached from the rotator cable and retracted. Fatty infiltration of the infraspinatus muscle before surgery was grade 2 in two patients and grade 3 in two patients. At follow-up, all patients had fatty infiltration of the infraspinatus muscle grade 3 on MRI. The partial subscapular repair was healed on MRI in patient 3. None of the patients had any signs of osteoarthritis on MRI before or after surgery.

Compared with the patients who were treated conservatively, the CMS and VAS pain and disability scores of the surgical group were similar before treatment and at 12 months follow-up. At 3 and 6 months after surgery, the clinical results were inferior to the non-operative group.

**Table 1.** Patient characteristics

Patient	Age (years)	Sex	Smoker	MRI, no. of ruptured tendons	MRI Patte	MRI Fuchs	Additional surgery
Group 1							
1	61	Female	Yes	2	3	3	
2	67	Male	No	2	3	2	
3	64	Male	No	3	3	3	Hamstring autograft subscapularis repair
4	62	Male	No	2	3	2	
Group 2							
1	72	Female		2	3	3	Non-surgical treatment
2	63	Female		1	3	2	Non-surgical treatment
3	62	Male		2	3	3	Non-surgical treatment
4	72	Female		3	3	–	Non-surgical treatment
5	57	Female		2	3	3	Non-surgical treatment

Group 1, surgical treatment, group 2, non-surgical treatment

## DISCUSSION

Clinical and radiological results after tendon autograft for reconstruction of the rotator cable were collected in four patients with a MRCT. On the MRI scan, 1 year after surgery, the rotator cable reconstruction disintegrated and failed; clinical results were not superior to the results after non-operative treatment with physiotherapy. Because of disappointing preliminary results and a vanishing reconstructed rotator cable on MRI during 1 year of inclusion, no further patients were included. When developing this new surgical procedure, we hypothesized that the procedure might have several advantages. This technique results in a biomechanical reconstruction leading to transporting force couples from the rotator cuff to the humeral head. As the remaining rotator cuff was attached to the rotator cable and not to the footprint, we were able to reattach the rotator cuff to the cable in irreparable cuff tears. With this technique, tension on the massive cuff tear gap was minimized by medializing the new rotator cable. The technique represents a reconstruction with the use of an autograft. The biceps tendon is easy to harvest and gives no graft reactions. In other studies, the biceps tendon was used as an augmentation of the rotator cuff with good clinical results. Although we observed improved clinical results in three out of four patients 1 year after surgery with the CMS and WORC exceeding the minimal important clinical difference of 10.4 points

**Table 2** Outcome scores in mean (range)

	Preop		3 months		6 months		12 months <sup>a</sup>	
	Group 1	Group 2	Group 1	Group 2	Group 1	Group 2	Group 1	Group 2
CMS pain	6.3 (0–10)	7.0 (0–15)	7.5 (5–10)	13.7 (10–15)	10.0 (5–10)	10.0 (5–15)	13.3 (10–15)	11.0 (0–15)
CMS activity	7.0 (4–12)	10.4 (4–14)	5.0 (4–6)	16.5 (15–19)	9.3 (4–15)	14.8 (12–20)	16.0 (10–20)	16.4 (8–20)
CMS mobility	17.5 (10–24)	23.6 (8–36)	10.0 (8–12)	26.0 (20–30)	14.5 (8–20)	27.2 (22–34)	20.6 (18–26)	30.8 (20–36)
CMS strength	12.5 (5–25)	9.46 (2–19)	12.5 (5–20)	9.65 (8–12)	14.3 (5–22)	10.4 (4–18)	19.7 (10–25)	9.88 (2–17)
CMS total	43.3 (31–32)	49.0 (26–73)	35.0 (28–42)	65.9 (61–73)	46.5 (28–67)	62.0 (51–69)	69.7 (53–80)	68.1 (30–81)
SST	5.5 (1–8)	–	4.75 (1–8)	–	5.3 (2–7)	–	6.3 (6–7)	–
WORC	55.3 (36–52)	–	43.3 (39–53)	–	47.7 (32–60)	–	60.3 (49–67)	–
VAS pain	45.0 (30–70)	60 (30–80)	56.3 (20–80)	27 (20–50)	37.5 (10–65)	38 (20–60)	16.7 (10–20)	26 (10–80)
VAS disability	53.3 (8–80)	54 (20–10)	65.0 (40–85)	35 (30–40)	46.3 (20–70)	42 (30–60)	40.0 (15–70)	30 (10–80)
VAS satisfaction	–	–	46.3 (40–50)	–	43.8 (5–60)	–	63.4 (45–85)	–

Group 1, surgical treatment; group 2, non-surgical treatment WORC depicted as a percentage of normal/maximum score aResults of three out of four patients

[19] and 282.6 points [20] respectively, MRI showed failure of the reconstructed rotator cable in all patients.

While performing the index operation, we used margin convergence to close the cuff partially to the reconstructed rotator cable, but on MRI scan at follow-up, the cuff was re-torn and retracted compared with the preoperative situation. The improvement in pain and function could not be attributed to the reconstruction of the rotator cable as this construct failed over time [21]. The clinical improvement over time in the surgical group was similar to the improvement noted in the control group, treated non-operatively with physiotherapy. In two randomized controlled studies about cuff repair versus conservative treatment of degenerative rotator cuff tears, good clinical improvement was also found after conservative treatment. These studies showed a mean improvement of the CMS of 16.8 points after 1 year [3] and 18.4 points after 2 years [22] following conservative treatment. In both studies, this was not significantly different from the surgically treated patients. In our control group, a mean improvement of the CMS of 19.1 points was found after 1 year.

The rotator cuff showed fatty infiltration (grade 3 in two out of four patients). This may have resulted in low healing capacity and eventually a detachment of the rotator cuff from the reconstructed rotator cable on the control MRI. Previous studies also show that this is a predictor for worse outcomes in cuff repairs [23], even in cases of successful repair [24]. Reconstruction of the rotator cable failed over time in all patients. The biceps tendon may have been degenerative, thus preventing ingrowth, although histological analyses show that a degenerated biceps tendon is still rich in collagen [25]. In one patient, a hamstring graft was used because of a missing long head of biceps during surgery. This may be a bias confounding the outcome. The study group is small and consisted only of four patients. In our study protocol, we decided to include patients for this new technique for 1 year, and then evaluate the clinical and radiological results. Because the construction failed in all patients, we decided to end this pilot study. There is a possibility that this technique might be successful in some patients when a larger group of patients would be operated. Comparing the results of our study with other studies using a biceps tendon graft for rotator cuff repair, a superior outcome was found when the biceps tendon was used for augmentation with an improvement of 44.1 points on the CMS by Cho et al. [26]. Also, the long-term outcome scores of the latissimus dorsi transfer as treatment for massive rotator cuff tears were better, with an increase of 27 points on the CMS [27].

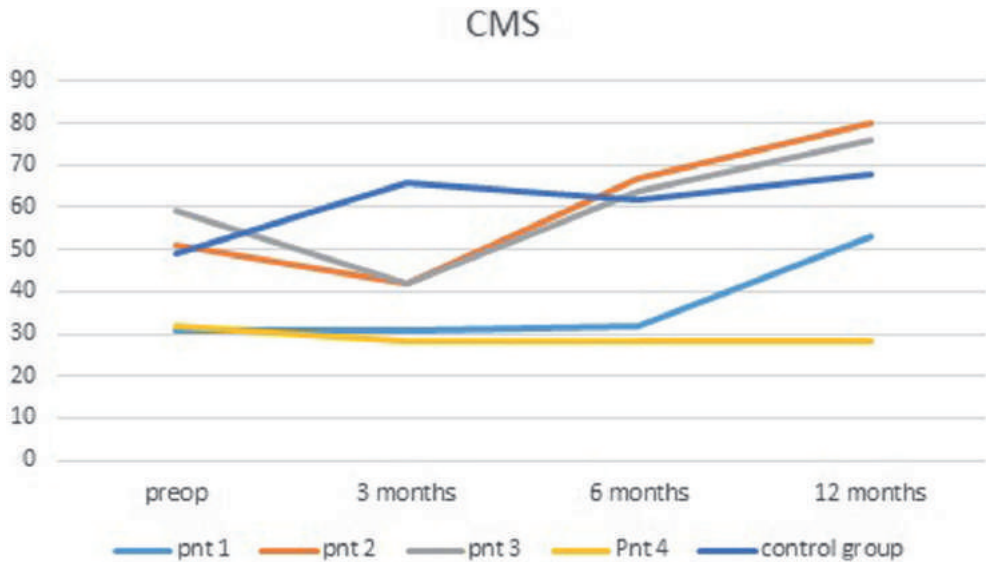


Figure 4. Total CMS scores per patient

Treating MRCTs remains a significant challenge for the clinicians. Several surgical options are available for patients with a MRCT if conservative treatment fail: debridement, long head of biceps tenotomy, partial repair, rotator cuff advancement, bridging graft repair, superior capsular reconstruction, subacromial spacer, and reverse total shoulder arthroplasty. The variability in patient characteristics, co-interventions, outcome reporting, and length of follow-up in studies on MRCTs complicates sound comparison of treatments [28]. Joint preserving procedures are preferably used in young patients; in the older population, reversed shoulder arthroplasty or maybe the subacromial balloon spacer might be indicated. The superior capsular reconstruction has become a popular surgical technique. The short-term results of superior capsular reconstruction show consistent improvement in shoulder functionality and pain reduction. However, on longer follow-up, decreased acromiohumeral intervals indicate dermal allograft elongation and persistent superior migration of the humerus [29]. Placement of the subacromial balloon spacer is a minimally invasive, technically simple procedure with favorable patient-reported outcomes at limited short-term follow-up. However, inherent methodological limitations and patient heterogeneity between studies using the subacromial spacer may impair the ability to fully characterize the long-term efficacy, particularly relative to other potential surgical options [30, 31].

## CONCLUSIONS

In conclusion, the arthroscopic reconstruction of the rotator cable using a tendon autograft failed over time in this pilot study, and showed no clinical benefit in comparison with the non-operative treatment with physiotherapy in patients with a MRCT. We therefore cannot recommend using this surgical procedure to treat patients with a massive rotator cuff tear.

### Abbreviations

CMS: Constant-Murley Score; MRCT: Massive rotator cuff tear; MRI: Magnetic resonance imaging; SST: Simple Shoulder Test; VAS: Visual analog scale; WORC: Western Ontario Rotator Cuff

### Acknowledgements

We would like to thank O.F.O Lambers Heerspink for his help with the database.

## REFERENCES

1. Lädermann A, Denard PJ, Collin P. Massive rotator cuff tears: definition and treatment. *Int Orthop*. 2009;39(12):2403–14.
2. Millett PJ, Warth RJ, Dornan GJ, et al. Clinical and structural outcomes after arthroscopic single-row versus double-row rotator cuff repair: a systematic review and meta-analysis of level I randomized clinical trials. *J Shoulder Elbow Surg*. 2014;23:586–97.
3. Lambers Heerspink FO, van Raay JJ, Koorevaar RC, et al. Comparing surgical repair with conservative treatment for degenerative rotator cuff tears: a randomized controlled trial. *J Shoulder Elbow Surg*. 2015;24:1274–81.
4. Yang J Jr, Robbins M, Reilly J, et al. The clinical effect of a rotator cuff retear: a meta-analysis of arthroscopic single-row and double-row repairs. *Am J Sports Med*. 2017;45:733–41.
5. Galatz LM, Ball CM, Teefey SA, et al. The outcome and repair integrity of completely arthroscopically repaired large and massive rotator cuff tears. *J Bone Joint Surg*. 2004;86(2):219–24.
6. Hein J, Reilly JM, Chae J, et al. Retear rates after arthroscopic single-row, double-row, and suture bridge rotator cuff repair at a minimum of 1 year of imaging follow-up: a systematic review. *Arthroscopy*. 2015;31:2274–81.
7. Steinhaus ME, Makhni EC, Cole BJ, et al. Outcomes after patch use in rotator cuff repair. *Arthroscopy*. 2016;32(8):1676–90.
8. Pennington WT, Bartz BA, Pauli JM, et al. Arthroscopic superior capsular reconstruction with acellular dermal allograft for the treatment of
9. massive irreparable rotator cuff tears: short-term clinical outcomes and the radiographic parameter of superior capsular distance. *Arthroscopy*. 2018;34:764–73.
10. Deprés-tremblay G, Chevrier A, Snow M, et al. Rotator cuff repair: a review of surgical techniques, animal models, and new technologies under development. *J Shoulder Elb Surg*. 2016;25(12):2078–85.
11. Veen EJ, Stevens M, Diercks RL. Biceps autograft augmentation for rotator cuff repair: a systematic review. *Arthroscopy*. 2018;34:1297–305.
12. Mesiha MM, Derwin KA, Sibole SC, et al. The biomechanical relevance of anterior rotator cuff cable tears in a cadaveric shoulder model. *J Bone Joint Surg Am*. 2013;95:1817–24.
13. Rahu M, Kolts I, Põldoja E, et al. Rotator cuff tendon connections with the rotator cable. *Knee Surg Sports Traumatol Arthrosc*. 2017;25:2047–50.
14. Veen EJ, Koorevaar CT, Diercks RL. Using the long head of biceps tendon autograft as an anatomical reconstruction of the rotator cable: an arthroscopic technique for patients with massive rotator cuff tears. *Arthrosc Tech*. 2018:e699–703.
15. Patte D. Classification of rotator cuff lesions. *Clin Orthop Relat Res*. 1990;254:81–6.
16. Lippitt SB, Harryman DT, Matsen FA. The shoulder: a balance of mobility and stability. Rosemont: American Academy of Orthopaedic Surgeons; 1993. p. p545–59.
17. Kirkley A, Alvarez C, Griffin S. The development and evaluation of a disease-specific quality-of-life questionnaire for disorders of the rotator cuff: the Western Ontario Rotator Cuff Index. *Clin J Sport Med*. 2003;13(2):84–92.
18. Price DD, McGrath PA, Rafii A, et al. The validation of visual analogue scales as ratio scale measures for chronic and experimental pain. *Pain*. 1983;17(1):45–56.
19. Fuchs B, Weishaupt D, Zanetti M, Hodler J, Gerber C. Fatty degeneration of the muscles of the rotator cuff: assessment by computed tomography versus magnetic resonance imaging. *J Shoulder Elb Surg*. 1999;8(6):599–605.


20. Kukkonen J, Kauko T, Vahlberg T, et al. Investigating minimal clinically important difference for constant score in patients undergoing rotator cuff surgery. *J Shoulder Elbow Surg.* 2013;22:1650–5.
21. Gagnier JJ, Robbins C, Bedi A, et al. Establishing minimally important differences for the American Shoulder and Elbow Surgeons score and the Western Ontario Rotator Cuff Index in patients with full-thickness rotator cuff tears. *J Shoulder Elbow Surg.* 2018;27:e166.
22. Burkhart SS. Reconciling the paradox of rotator cuff repair versus debridement: a unified biomechanical rationale for the treatment of rotator cuff tears. *Arthroscopy.* 1994;10(1):4–19.
23. Kukkonen J, Joukainen A, Lehtinen J, et al. Treatment of non-traumatic rotator cuff tears: a randomised controlled trial with one-year clinical results. *Bone Joint J.* 2014;97:1729–37.
24. McElvany MD, McGoldrick E, Gee AO, et al. Rotator cuff repair: published evidence on factors associated with repair integrity and clinical outcome. *Am J Sports Med.* 2015;43:491–500.
25. Gladstone JN, Bishop JY, Lo IK, et al. Fatty infiltration and atrophy of the rotator cuff do not improve after rotator cuff repair and correlate with poor functional outcome. *Am J Sports Med.* 2007;35:719–28.
26. Mazzocca AD, McCarthy MBR, Ledgard FA, et al. Histomorphologic changes of the long head of the biceps tendon in common shoulder pathologies. *Arthroscopy.* 2013;29:972–81.
27. Cho NS, Yi JW, Rhee YG. Arthroscopic biceps augmentation for avoiding undue tension in repair of massive rotator cuff tears. *Arthroscopy.* 2009; 25(2):183–91.
28. El-Azab HM, Rott O, Irlenbusch U. Long-term follow-up after latissimus dorsi transfer for irreparable posterosuperior rotator cuff tears. *J Bone Joint Surg Am.* 2015;97:462–9.
29. Kooistra B, Gurnani N, Weening A, van den Bekerom M, van Deurzen D. Low level of evidence for all treatment modalities for irreparable posterosuperior rotator cuff tears. *Knee Surg Sports Traumatol Arthrosc.* 2019;27(12):4038–48. <https://doi.org/10.1007/s00167-019-05710-0> Epub 2019 Sep 18.
30. Zastrow RK, London DA, Parsons BO, Cagle PJ. Superior capsule reconstruction for irreparable rotator cuff tears: a systematic review. *Arthroscopy.* 2019;35(8): 2525–2534.e1. <https://doi.org/10.1016/j.arthro.2019.02.053>.
31. Malahias MA, Brilakis E, Avramidis G, Antonogiannakis E. Satisfactory mid-term outcome of subacromial balloon spacer for the treatment of irreparable rotator cuff tears. *Knee Surg Sports Traumatol Arthrosc.* 2019. <https://doi.org/10.1007/s00167-019-05485-4>.
32. Stewart RK, Kaplin L, Parada SA, Graves BR, Verma NN, Waterman BR. Outcomes of subacromial balloon spacer implantation for massive and irreparable rotator cuff tears: a systematic review. *Orthop J Sports Med.* 2019;7(10):2325967119875717. <https://doi.org/10.1177/2325967119875717> eCollection 2019 Oct.







part three



**Trends and controversies**  
**in the treatment of the**  
**ageing shoulder**



**Appropriate care for orthopedic patients: effect of implementation of the Clinical Practice Guideline for Diagnosis and Treatment of Subacromial Pain Syndrome in the Netherlands**

Egbert J D Veen  
Martin Stevens  
Cornelis T Koorevaar  
Ron L Diercks

*Acta Orthopaedica*  
2019, 90(3), 191-195.

## ABSTRACT

### **Background and purpose**

The multidisciplinary Clinical Practice Guideline for diagnosis and treatment of subacromial pain syndrome (SAPS) was created in 2012 by the Dutch Orthopedic Association. In brief, it stated that SAPS should preferably be treated nonoperatively. We evaluated the effect of the implementation of the guideline on the number of shoulder surgeries for SAPS in the Netherlands (17 million inhabitants).

**Patients and methods:** An observational study was conducted with the use of aggregated data from the national database of the Dutch Health Authority from 2012 to 2016. Information was collected on patients referred to and seen at orthopedic departments. Data from the following Diagnoses Related Groupings were analyzed: 1450 (tendinitis supraspinatus) and 1460 (rotator cuff tear).

### **Results**

In 2016 fewer patients were diagnosed with tendinitis supraspinatus than in 2012—a decrease from 49,491 to 44,662 (10%). Of the patients diagnosed with tendinitis, 14% were treated surgically in 2012; this number dropped to 9% by 2016. More patients with a rotator cuff tear were diagnosed in 2016 than in 2012, an increase from 17,793 to 23,389 (32%), fewer were treated surgically: 30% in 2012, compared with 25% in 2016.

### **Interpretation**

After introducing the multidisciplinary Clinical Practice Guideline “Diagnosis and treatment of subacromial pain syndrome,” a decrease in shoulder surgeries for related diagnoses was observed in the Netherlands. The introduction and dissemination of this guideline seems to have contributed to the implementation of more appropriate health care and prevention of unnecessary surgeries.

## INTRODUCTION

Shoulder pain is a frequent complaint in the general population, with an incidence of 0.8–2.3% and a lifetime prevalence of up to 67% (Urwin et al. 1998, Luime et al. 2004). It is mainly seen in women over age 45 (Greving et al. 2012). The most frequent complaint is pain at the shoulder with overhead activities, and pain at night.

Neer (1983) developed the concept of “impingement syndrome,” also called rotator cuff disease, bursitis, and supraspinatus tendinitis. None of these names cover the complex origin of subacromial pain with a painful arc, which nowadays is called “subacromial pain syndrome” (SAPS) (Papadonikolakis et al. 2011, Diercks et al. 2014b). Most of the symptoms usually resolve within a few months. Some patients show persistent symptoms despite physiotherapy and are referred to orthopedic surgeons to discuss open or arthroscopic bursectomy, acromioplasty, and/or rotator cuff repair.

In recent years increasing scientific evidence shows that patients’ results from surgical interventions are not better than treatment with physiotherapy and/or steroid injections (Dorrestijn et al. 2009, Björnsson Hallgren et al. 2017, Ketola et al. 2017). A randomized controlled trial (RCT) showed no benefit of acromioplasty compared with sham surgery or nonoperative treatment (Beard et al. 2018).

A clinical practice guideline for diagnosis and treatment of subacromial pain syndrome based on the available scientific evidence was created by the Dutch Orthopedic Society in 2012. The major recommendations were: SAPS should preferably be treated nonoperatively; patients who do not respond to exhaustive nonoperative treatment can be offered surgery; asymptomatic rotator cuff tears should not be treated surgically; when surgical repair of symptomatic rotator cuff tears is considered, the size of the tear, the condition of the muscles, and age and activity level of the patient are important factors to consider in the context of patient expectations; surgical treatment of tendinosis calcarea is not recommended.

To disseminate the guideline, presentations were given to the Dutch Orthopedic Society, the Rehabilitation Society and the Dutch Shoulder and Elbow Society. The guidelines were published in the Dutch Orthopedic Journal, the Dutch General Medical Journal (Diercks et al. 2014a), and Acta Orthopædica 2014 (Diercks et al. 2014b). Multiple presentations were held for national and regional symposia, physical therapists, and GPs.

We have now examined whether the referral and treatment patterns have changed following the presentation of the clinical practice guideline for SAPS.

## PATIENTS AND METHODS

This observational study was conducted with use of aggregated data from the national database of the Dutch Health Authority from 2012 until 2016. All patients seen by a medical specialist in the Netherlands have specific codes registered for every diagnosis and treatment. The following diagnosis-related groupings (DRG) (in Dutch DBC, Diagnose Behandel Combinatie) are applicable to the SAPS guideline:

- 1450: tendinitis supraspinatus/ biceps, i.e., impingement;
- 1460: rotator cuff/ biceps tendon tear.

We excluded the code 1480 “AC/SC disorders” and 1487 “other enthesiopathy of shoulder/elbow.”

The following surgical codes are related:

- 38100: acromioplasty;
- 38177 surgery on shoulder bursa.

To examine whether the treatment regimens for SAPS have changed since presentation of this new guideline we extracted data from the Dutch Health Authority (NZA) (Zorgautoriteit 2016). After choosing a DRG all declared subsequent surgical procedures can be found and calculated. The NZA is an autonomous administrative authority under the Dutch Ministry of Health, Welfare and Sports. The NZA has a database with nationwide data of all patients diagnosed at any Dutch hospital, and all interventions such patients underwent within the chosen diagnostic criteria (Zorgautoriteit 2018). As stated before, registry in this database is mandatory using a fixed list with diagnoses to choose from. Every Dutch orthopedic surgeon is obliged to use these codes for billing of the costs at the insurance companies.

This list has not been changed during the study period. Only 1 DRG can be chosen for the shoulder complaint at the first visit. This database starts from 2012 and contains only anonymous and aggregated data. We looked within the groups of the above-mentioned DRGs from January 1, 2012 to December 31, 2016 and registered the number of patients who had subsequent surgery. The numbers in the database were complete for 2012, 2013, and 2014. As a result of the ongoing billing process at the time of this study the numbers for the year 2015 were 90% completed and the numbers for 2016 were 75% completed. The numbers of these years are extrapolated to 100% in order to make a valid comparison.

The Dutch healthcare insurance system requires referral by a GP before a patient can visit a medical specialist such as an orthopedic surgeon. To calculate the incidence of DRGs, and thus the trend in referrals by mostly GPs, information was gathered from the Dutch Central Bureau of Statistics (Statline 2018).



Additionally, an online survey (see Supplementary data) was performed with a small cohort of GPs and orthopedic surgeons. GPs were randomly selected from a database of the university and the orthopedic surgeons were selected from the Dutch orthopedic association database. All of the invited GPs (n = 33) and orthopedic surgeons (n = 23) filled in the form. They were asked about their experiences with shoulder complaints, the guideline, and if they changed their treatment strategies as a result of the guideline.

## Statistics

Descriptive statistics were used for the annual incidence rates of referred patients for a specific DRG per 100,000 inhabitants. To get an impression of the effect of the dissemination of the guideline, total numbers of DRGs in the Netherlands were calculated and compared with the baseline year (2012) and with each subsequent year. 95% confidence intervals (CI) of the difference between these 2 proportions were calculated (Fleiss et al. 2013). SAS version 9.4 (SAS Institute, Cary, NC, USA) was used.

## Ethics, funding, and potential conflicts of interest

This study was reviewed and approved by the medical ethical committee of University Medical Center Groningen (register: 201501203-2018/259). There was no special funding for this study and there is no potential conflict of interest to be declared by any of the authors.

# RESULTS

## Incidence

From 2012 to 2016 a total of 237,960 patients were diagnosed by orthopedic surgeons with DRG 1450 “tendinitis supraspinatus/biceps, i.e., impingement” and 97,900 patients with DRG 1460 “rotator cuff/biceps tendon tear.” In 2016, fewer patients were diagnosed with a tendinitis supraspinatus/ biceps, i.e., impingement (DRG 1450) compared with 2012, a decrease of 10%. More patients with rotator cuff or biceps tendon tear (DRG 1460) were diagnosed in 2016 than in 2012, an increase of 32% (Table 1). The referral pattern to orthopedic departments changed between 2012 and 2016. For DRG 1450 the incidence decreased from 2.96 to 2.63 per 100,000 inhabitants; for DRG 1460 the incidence increased from 1.06 to 1.38 per 100,000 inhabitants.

## Surgery for DRG 1450 tendinitis supraspinatus/ biceps, i.e., impingement

Of the patients diagnosed with DRG, 1,450 14% underwent surgery in 2012. This decreased to 9% in 2016 (Table 1). This is a statistically significant drop when comparing

2012 with 2014, 2015, and 2016, but also when comparing the subsequent years with each other (Table 2).

### Surgery for DRG 1460 rotator cuff or biceps tendon tear

Of the 1,460 patients diagnosed with a DRG, 30% underwent surgery in 2012. The percentage of referred patients who had surgery decreased to 25% in 2016 (Table 1). This is a statistically significant drop when comparing 2012 with 2015 and 2016, but also when comparing 2014, 2015, and 2016 with each other (Table 3).

### Surgical codes

When looking at surgical codes a statistically significant decrease in acromioplasties (41%) and an increase in bursectomies (18%) is seen over the years (Table 4).

An overview of the percentages of the total referred patients for each DRG treated surgically is depicted in Figure 1.

To gain an impression of the experiences with the guideline an online survey (see Supplementary data) was performed on shoulder surgeons and GPs. 23 shoulder surgeons and 33 GPs were reached. All but 2 shoulder surgeons were familiar with the guideline and 19 considered it helpful with treating their patients with SAPS; 19 surgeons stated that less than 10% of the SAPS patients were treated surgically after the guideline was published.

2 out of 33 GPs were familiar with the SAPS guideline but 11 of the GPs stated that they had changed their treatment the past years; more patients are treated nonoperatively and not referred to an orthopedic specialist.

**Table 1.** Numbers and incidences (per 100,000 inhabitants in the Netherlands) of DRG divided by nonoperative and operative treatment

	Tendinitis supraspinatus/biceps, i.e. impingement (DRG 1450)				Rotator cuff or biceps tendon tear (DRG 1460)			
	Referred	Incidence	Non-operative	Operative	Referred	Incidence	Non-operative	Operative
2012	49,591	2.96	42,443	7,148	17,793	1.06	12,597	5,196
2013	48,945	2.92	42,076	6,869	20,130	1.20	14,191	5,939
2014	47,401	2.82	41,375	6,026	21,156	1.26	15,015	6,141
2015 <sup>a</sup>	47,361	2.80	42,551	4,810	23,643	1.40	17,337	6,306
2016 <sup>a</sup>	44,662	2.63	40,585	4,077	23,389	1.38	17,593	5,796

<sup>a</sup> Numbers extrapolated to 100%.

**Table 2.** Differences in patients who had surgery for DRG 1450 (tendinitis supraspinatus/biceps, i.e., impingement) for each year compared with 2012 and subsequent years

Baseline	versus	Difference (Confidence interval)
2012	2013	0.00 (-0.01 to 0.00)
2012	2014	-0.02 (-0.02 to -0.01) a
2012	2015	-0.04 (-0.05 to -0.04) a
2012	2016	-0.05 (-0.06 to -0.05) a
2013	2014	-0.01 (-0.02 to -0.01) a
2014	2015	-0.03 (-0.03 to -0.02) a
2015	2016	-0.01 (-0.01 to -0.01) a

<sup>a</sup> Significant difference.

**Table 3.** Differences in patients who had surgery for DRG 1460 (rotator cuff or biceps tendon tear) for each year compared with 2012 and subsequent years

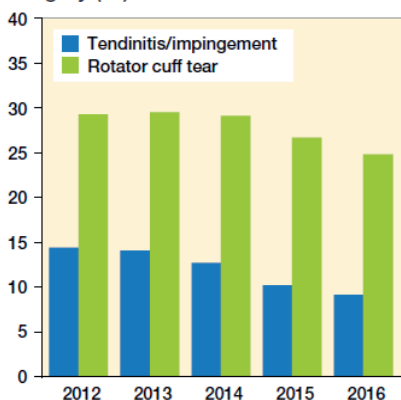
Baseline	versus	Difference (Confidence interval)
2012	2013	0.00 (-0.01 to 0.01)
2012	2014	0.00 (-0.11 to 0.01)
2012	2015	-0.03 (-0.03 to -0.02) a
2012	2016	-0.04 (-0.05 to -0.04) a
2013	2014	0.00 (-0.01 to 0.00)
2014	2015	-0.02 (-0.03 to -0.02) a
2015	2016	-0.02 (-0.03 to -0.01) a

<sup>a</sup> Significant difference.

**Table 4.** Surgical procedures

Year	Acromioplasty	Shoulder bursectomy
2012	9,025	1,974
2013	8,625	2,377
2014	8,263	2,545
2015	6,803	2,488
2016	5,310	2,335

**Surgery (%)**



**Figure 1.** Percentages of surgeries of total referred patients for each DRG.

## DISCUSSION

This study was conducted to investigate the effect of the introduction of the Clinical Practice Guideline for Subacromial Pain Syndrome. The results show that after publication of the guideline, the number of patients referred with the diagnosis of “impingement” or “tendinitis” decreased by 10%. Surgery decreased, by 37% and 17% respectively, in the SAPS and rotator cuff tear-related group. The proportion of surgical treatment for “tendinitis” and “rotator cuff tear” decreased from 18% in 2012 to 15% in 2016. Also, a decrease in acromioplasties was observed. Despite most GPs not being familiar with the SAPS guideline they had changed their practice with fewer referrals.

Our results are in line with international shifts in the treatment of SAPS and rotator cuff tears, most likely as a result of emerging evidence. In Finland a drop in acromioplasties is seen from 1998 to 2011 (Paloneva et al. 2015). In Australia the number of patients having a rotator cuff repair increased over the years 2001–2013 (Thorpe et al. 2016). The same trend is seen in the United States, with a decrease in acromioplasties and a rise in rotator cuff surgeries (Mauro et al. 2012). The international rise in patients undergoing surgical repair for a rotator cuff tear may be the result of improved surgical options during the latest 15 years.

The Clinical Practice Guideline for Diagnosis and Treatment of Subacromial Pain Syndrome was completed in 2012. Since 2012 more scientific evidence supports the recommendations of the Clinical Practice Guideline. The most recent RCT with surgical, sham surgical, and nonoperative treatments for SAPS showed no benefit of surgery (Beard et al. 2018). The RCT of Farfaras et al. (2016) showed no difference between open acromioplasty, arthroscopic acromioplasty, and physiotherapy in the treatment of SAPS after 2–3 years, but somewhat better results for the surgical groups compared with the physiotherapy group after long-term follow-up (Farfaras et al. 2018). Ketola et al. (2017) saw no benefit of surgical treatment for SAPS after 10 years follow-up of an RCT. A review of 2014 saw a benefit of physiotherapy compared with controls (Gebremariam et al. 2014).

Several recent RCTs showed no benefit of surgery for asymptomatic degenerative rotator cuff tears compared with nonoperative treatment (Moosmayer et al. 2014, Lambers Heerspink et al. 2015). No difference was seen either when these treatments were combined with an acromioplasty (Kukkonen et al. 2015).

Several institutes have recognized elements that increase the impact of clinical guidelines, like the standards of trustworthiness developed by the IOM (Institute of Medicine) of the American National Academies, and derivative products like physician–patient guides that help provide more practical information. The Dutch guideline fulfills

these conditions. Nevertheless, several clinical guidelines like those produced by NICE (National Institute for Health and Care Excellence) in the UK and other national bodies appear to play a limited part in orthopedic decision-making (Grove et al. 2016).

Although formal codified knowledge in the form of clinical guidelines still appears to play a modest part in orthopedic surgery clinical practice decision-making, the coincidence of new high-level scientific evidence provided by well-designed and performed RCTs and the development of clinical guidelines will have an impact on orthopedic clinical decision-making (Khan et al. 2013). We observed this effect in our study period after implementation of our clinical guideline and the publication of several RCTs that confirmed the conclusions of our guideline.

The results of the survey show that the treatment strategies of the orthopedic surgeons are roughly in line with the guidelines; fewer patients were treated surgically. However, only 2 out of 33 GPs were familiar with the SAPS guideline. All GPs used the National General Practitioner Guideline (NHG) "shoulder complaints" from 2008. We found a decline in referrals from GPs, but still it is unclear whether this can be attributed to the guideline.

Clinical orthopedic practice is difficult to change, as shown in our study: SAPS is still treated surgically in 10% of cases. This is also seen in the treatment of degenerative meniscal tears. Several studies and clinical guidelines indicate that arthroscopic debridement is of no benefit (Sihvonen et al. 2013, Thorlund et al. 2015) but arthroscopies on patients with degenerative meniscal tears are still performed in the Netherlands (Rongen et al. 2018).

One of the flaws is that the data of this study were derived from the database of the NZA, which started in 2012 with no information preceding that. The effects we found may be the result of a trend based on earlier reports. Another limitation is the extrapolation of the database numbers for 2015 and 2016 to compare them with the preceding years. Although this may influence the total number of patients with that diagnosis, the relative number of surgical vs. nonoperative treatments is not influenced because this is only recorded within the diagnostic group. The surgical codes are used for a sole procedure or as part of other surgery, such as arthroscopic lateral clavicular resection, therefore the numbers are not always limited to DRG 1450 and 1460 but may also be registered from other DRGs. On the basis of registration inaccuracies, a distal clavicle resection could have been performed additional to an acromioplasty, or vice versa. As the aim of the study was to identify the number of procedures before and after the publication of the guideline, and the registration system did not change, this will not have had an effect on the study results.

In summary, the introduction and dissemination of this guideline seem to have contributed to implementation of more appropriate healthcare and prevention of unnecessary surgeries. Although GPs refer fewer patients for SAPS, their education can still be improved.

### Supplementary data

The online survey is available as supplementary data in the online version of this article, <http://dx.doi.org/10.1080/17453674.2019.1593641>

EV, MS, CK, and RD all participated in the conception and design of the study. EV was responsible for acquisition of the data. EV and MS did the statistical analysis. All authors critically revised the manuscript for important intellectual content and approved the final version of the manuscript.

The authors would like to thank Roy Stewart and Ruth Rose for their contribution to the study and the analysis.

Acta thanks Lars Evert Adolfsson and Jeppe Vejlgard Rasmussen for help with peer review of this study.

## REFERENCES

- Beard DJ, Rees JL, Cook JA, Rombach I, Cooper C, Merritt N, Shirkey BA, Donovan JL, Gwilym S, Savulescu J. Arthroscopic subacromial decompression for subacromial shoulder pain(CSAW): a multicentre, pragmatic, parallel group, placebo-controlled, three-group, randomised surgical trial. *Lancet* 2018; 391(10118): 329-38.
- Björnsson Hallgren, H C, Adolfsson, L E, Johansson K, Öberg B, Peterson A, Holmgren T M. Specific exercises for subacromial pain: good results maintained for 5 years. *Acta Orthop* 2017, 88(6), 600-5.
- Diercks R L. Practice guideline "diagnosis and treatment of the subacromial pain syndrome." *Ned Tijdschr Geneesk* 2014a; 158: A6985.
- Diercks R, Bron C, Dorrestijn O, Meskers C, Naber R, de Ruitter T, Willems J, Winters J, van der Woude, Henk Jan. Guideline for diagnosis and treatment of subacromial pain syndrome: a multidisciplinary review by the Dutch Orthopaedic Association. *Acta Orthop* 2014b; 85(3): 314-22.
- Dorrestijn O, Stevens M, Winters J C, van der Meer K, Diercks R L. Conservative or surgical treatment for subacromial impingement syndrome? A systematic review. *J Shoulder Elbow Surg* 2009; 18(4): 652-60.
- Farfaras S, Sernert N, Hallström E, Kartus J. Comparison of open acromioplasty, arthroscopic acromioplasty and physiotherapy in patients with subacromial impingement syndrome: a prospective randomised study. *KSSTA* 2016; 24(7): 2181-91.
- Farfaras, S, Sernert N, Rostgard-Christensen L, Hallstrom E, Kartus J T. Subacromial decompression yields a better clinical outcome than therapy alone: a prospective randomized study of patients with a minimum 10-year follow-up. *J Sports Med* 2018; 46(6): 1397-407.
- Fleiss J L, Levin B, Paik M C. Statistical methods for rates and proportions. Chichester: Wiley; 2013.
- Gebremariam L, Hay E M, van der Sande R, Rinkel W D, Koes B W, Huisstede B M. Subacromial impingement syndrome: effectiveness of physiotherapy and manual therapy. *Br J Sports Med* 2014; 48(16): 1202-8.
- Greving K, Dorrestijn O, Winters J C, Groenhof F, Van der Meer K, Stevens M, Diercks R L. Incidence, prevalence, and consultation rates of shoulder complaints in general practice. *Scand J Rheumatol* 2012; 41(2): 150-5.
- Grove A, Johnson R, Clarke A, Currie G. Evidence and the drivers of variation in orthopaedic surgical work: a mixed method systematic review. *Health Syst Policy Res* 2016; 3: 1.
- Ketola S, Lehtinen J T, Arnala I. Arthroscopic decompression not recommended in the treatment of rotator cuff tendinopathy: a final review of a randomised controlled trial at a minimum follow-up of ten years. *Bone Joint J* 2017; 99(6): 799-805.
- Khan H, Hussain N, Bhandari M. The influence of large clinical trials in orthopedic trauma: do they change practice? *J Orthop Trauma* 2013; 27(12): e274.
- Kukkonen J, Joukainen A, Lehtinen J, Mattila K T, Tuominen E K, Kauko T, Aarimaa V. Treatment of nontraumatic rotator cuff tears: a randomized controlled trial with two years of clinical and imaging follow-up. *J Bone Joint Surg Am* 2015; 97(21): 1729-37.
- Lambers Heerspink F O, van Raay J J, Koorevaar R C, van Eerden P J, Westerbeek R E, van 't Riet E, van den Akker-Scheek I, Diercks R L. Comparing surgical repair with conservative treatment for degenerative rotator cuff tears: a randomized controlled trial. *J Shoulder Elbow Surg* 2015; 24(8): 1274-81.
- Luime J J, Koes B W, Hendriksen I, Burdorf A, Verhagen A P, Miedema H S, Verhaar J. Prevalence and incidence of shoulder pain in the general population: a systematic review. *Scand J Rheumatol* 2004; 33(2): 73-81.
- Mauro C S, Jordan S S, Irrgang J J, Harner C D. Practice patterns for subacromial decompression and rotator cuff repair: an analysis of the American Board of Orthopaedic Surgery database. *J Bone Joint Surg Am* 2012; 94(16): 1492-9.

- Moosmayer S, Lund G, Seljom U S, Haldorsen B, Svege I C, Hennig T, Pripp A H, Smith H. Tendon repair compared with physiotherapy in the treatment of rotator cuff tears: a randomized controlled study in 103 cases with a five-year follow-up. *J Bone Joint Surg Am* 2014; 96(18): 1504-14.
- Neer C S. Impingement lesions. *Clin Orthop Rel Res* 1983; (173): 70-7. Paloneva J, Lepola V, Karppinen J, Ylinen J, Aarimaa V, Mattila V M. Declining incidence of acromioplasty in Finland. *Acta Orthop* 2015; 86(2): 220-4.
- Papadonikolakis A, McKenna M, Warme W, Martin B I, Matsen III F A. Published evidence relevant to the diagnosis of impingement syndrome of the shoulder. *J Bone Joint Surg Am* 2011; 93(19): 1827-32.
- Rongen J J, van Tienen T G, Buma P, Hannink G. Meniscus surgery is still widely performed in the treatment of degenerative meniscus tears in the Netherlands. *Knee Surg Sports Traumatol Arthrosc* 2018; 26(4): 1123-9.
- Sihvonen R, Paavola M, Malmivaara A, Itälä A, Joukainen A, Nurmi H, Kalske J, Järvinen T L. Arthroscopic partial meniscectomy versus sham surgery for a degenerative meniscal tear. *N Engl J Med* 2013; 369(26): 2515-24.
- Statline C. Centraal bureau voor de statistiek. Bevolking kerncijfers Identifier: 37296ned, <http://opendata.cbs.nl/statline>
- Thorlund J B, Juhl C B, Roos E M, Lohmander L S. Arthroscopic surgery for degenerative knee: systematic review and meta-analysis of benefits and harms. *BMJ* 2015; 350: h2747.
- Thorpe A, Hurworth M, O'Sullivan P, Mitchell T, Smith A. Rising trends in surgery for rotator cuff disease in Western Australia. *Aust NZ J Surg* 2016; 86(10): 801-4.
- Urwin M, Symmons D, Allison T, Brammah T, Busby H, Roxby M, Simmons A, Williams G. Estimating the burden of musculoskeletal disorders in the community: the comparative prevalence of symptoms at different anatomical sites, and the relation to social deprivation. *Ann Rheum Dis* 1998; 57(11): 649-55.
- Zorgautoriteit. Open Data Van De Nederlandse Zorgautoriteit 2016; [http:// www.opendisdata.nl](http://www.opendisdata.nl)
- Zorgautoriteit. 2018; <https://www.nza.nl/english>







# Degenerative rotator cuff tears: to remain untouched?

Egbert J. D. Veen  
Cornelis T. Koorevaar

*Nederlands Tijdschrift voor Orthopaedie*  
2020, 27 (1), 19-20  
invited paper

## INTRODUCTION

In recent years, the number of degenerative rotator cuff repairs is rising in contrast to the significant drop of surgery cases for other degenerative diseases like the meniscal tears in elderly patients. Most patients with degenerative rotator cuff tears are successfully treated conservatively, while the (surgically) repaired rotator cuff tendons show re-tear rates of 40-70 % on the long term.<sup>1</sup> On the short-term, comparable results are seen in patients with degenerative rotator cuff tears treated conservatively or operatively.

## PRO SURGERY

Arthroscopic rotator cuff repair is a highly successful operation, with a low complication rate that can be performed under regional plexus anesthesia. Short-term results of the patients treated with a rotator cuff repair in RCT's were comparable with the results in patients treated conservatively, but clinical outcome in the surgically treated patients with a healed rotator cuff was superiorly to the outcome in the patients treated conservatively.<sup>2,3</sup> Re-tears after surgery are noted, most re-tears are small to medium size and well tolerated by patients.<sup>4</sup> More research has to be done to identify patients with a low risk for re-tears after surgery. As age and tobacco abuse are two of the most important risk factors, preferably non-smoking and younger patients should be offered a surgical cuff repair.<sup>5,6</sup>

As recent trials showed no clinically important difference at short term follow up between surgical and conservative treatment of atraumatic rotator cuff tears, long term results were clinical significantly better if patients were operated.<sup>7</sup> There was a significant and clinical important difference in outcomes as related to the measurement of strength. In patients treated conservatively, the majority demonstrated tear enlargement with a functional decline over time.<sup>1,8</sup> If these patients are treated conservatively first and the tear enlarges over time, the tear could be too large to be repaired by the time of the follow up.<sup>9</sup> Therefore we should not hesitate to operate patients for a rotator cuff repair, after a failed conservatively treatment of at least 3 months.

## CONTRA SURGERY

Atraumatic rotator cuff tears are encountered in the elderly population, and these numbers increase with age respectively. Most atraumatic rotator cuff tears are asymptomatic. The natural course of symptomatic degenerative rotator cuff tears are benign with most patients doing well with a conservative treatment of physiotherapy

and injection therapy.<sup>10</sup> The results of the surgical repairs of the degenerative cuff tendons show disappointing high rates of re-tears.<sup>1</sup> The most important risk factor of re-tears is age.<sup>6</sup> Atraumatic cuff tendons represent a degenerative process in the elderly population and is primarily a biological problem. Why should we treat a biological problem with a biomechanical solution?

RCT's comparing results after conservative treatments and rotator cuff repair in patients with a degenerative cuff tear, showed no clinical important difference after 1 and 2 years follow up.<sup>2,3</sup> In a recent pragmatic study all patients with degenerative rotator cuff tears were initially treated conservatively. After three months, 80% of these patients decided not to have surgery.<sup>8</sup> In literature, questions were posted about the enlargement of tears and the effect on symptoms on the long term when patients were treated conservatively.<sup>9</sup> Long term results of conservatively treated patients however showed lasting and good clinical results.<sup>11</sup> In this study, clinical outcome after 5 years showed similar results in the patients treated conservatively, as in the group that was operated 3 months after the start of the trial.

After surgical repair of atraumatic cuff tears, high re-tear rates were found at short term follow up, rising to more than 50 % after the following 10 years.<sup>1</sup> We should not advise performing surgery with such a high complications rate. Conservative treatment with physiotherapy is less prone to complications and less expensive than surgery. Therefore, a conservative approach should be advocated as the treatment modality to atraumatic rotator cuff tear.<sup>11</sup> Physiotherapy should be offered for at least 3 months, preferably executed by a sub-specialized therapist being a member of a Dutch 'shoulder-network' offering evidence based exercises.<sup>8</sup>

## GENERAL CONCLUSION

The evidence in literature suggests that all atraumatic rotator cuff repairs should be treated conservatively for at least 3 months. If conservative treatment fails, different treatment options based on risk factors should be considered. Factors for a successful rotator cuff repair are younger age, no smoking addiction and the size of the tear. Patient's prognosis should be discussed and further treatment plans should be made with the patient, using shared decision making. By that, community expenses can be restrained and effective care can be provided. Rotator cuff repair is still a viable option for selected patients in which conservative treatment has failed.

## REFERENCES

1. Randelli, P. S., Menon, A., Nocerino, E., Aliprandi, A., Feroldi, F. M., Mazzoleni, M. G. et al. Long-term Results of Arthroscopic Rotator Cuff Repair: Initial Tear Size Matters: A Prospective Study on Clinical and Radiological Results at a Minimum Follow-up of 10 Years. *The American Journal of Sports Medicine* 2019;47(11): 2659-2669.
2. Kukkonen, J., Joukainen, A., Lehtinen, J., Mattila, K. T., Tuominen, E. K. J., Kauko, T. et al. Treatment of non-traumatic rotator cuff tears: A randomised controlled trial with one-year clinical results. *The bone & joint journal* 2014; 96(1): 75-81.
3. Heerspink, F. O. L., van Raay, J. J., Koorevaar, R. C., van Eerden, P. J., Westerbeek, R. E., van't Riet, E. et al. Comparing surgical repair with conservative treatment for degenerative rotator cuff tears: a randomized controlled trial. *Journal of Shoulder and Elbow Surgery* 2015; 24(8): 1274-1281.
4. Collin, P., Kempf, J. F., Molé, D., Meyer, N., Agout, C., Saffarini, M., & Godenèche, A. Ten-year multicenter clinical and MRI evaluation of isolated supraspinatus repairs. *JBJS* 2017; 99(16): 1355-1364.
5. Altintas, B., Anderson, N. L., Pitta, R., Buckley, P. S., Bhatia, S., Provencher, M. T., & Millett, P. J. Repair of Rotator Cuff Tears in the Elderly: Does It Make Sense? A Systematic Review. *The American Journal of Sports Medicine* 2019: DOI: 0363546519834574.
6. Rashid, M. S., Cooper, C., Cook, J., Cooper, D., Dakin, S. G., Snelling, S., & Carr, A. J. Increasing age and tear size reduce rotator cuff repair healing rate at 1 year: Data from a large randomized controlled trial. *Acta orthopaedica* 2017; 88(6): 606-611.
7. Ramme, A. J., Robbins, C. B., Patel, K. A., Carpenter, J. E., Bedi, A., Gagnier, J. J., & Miller, B. S. Surgical Versus Nonsurgical Management of Rotator Cuff Tears: A Matched-Pair Analysis. *J Bone Joint Surg Am* 2019; 101(19): 1775-1782.
8. Dunn, W. R., Kuhn, J. E., Sanders, R., An, Q., Baumgarten, K. M., Bishop, J. Y. et al, 2013 Neer Award: predictors of failure of nonoperative treatment of chronic, symptomatic, full-thickness rotator cuff tears. *Journal of Shoulder and Elbow Surgery* 2016; 25(8): 1303-1311.
9. Keener JD, Galatz LM, Teefey SA, Middleton WD, Steger-May K, Stobbs-Cucchi G, Patton R, Yamaguchi K. A prospective evaluation of survivorship of asymptomatic degenerative rotator cuff tears. *J Bone Joint Surg Am* 2015; 97(2): 89-98.
10. Ryösä, A., Laimi, K., Äärimaa, V., Lehtimäki, K., Kukkonen, J., & Saltychev, M. Surgery or conservative treatment for rotator cuff tear: a meta-analysis. *Disability and Rehabilitation* 2017; 39(14): 1357-1363.
11. Boorman, R. S., More, K. D., Hollinshead, R. M., Wiley, J. P., Mohtadi, N. G., Lo, I. K., & Brett, K. R. What happens to patients when we do not repair their cuff tears? Five-year rotator cuff quality-of-life index outcomes following nonoperative treatment of patients with full-thickness rotator cuff tears. *Journal of Shoulder and Elbow Surgery* 2018; 27(3): 444-448.







**General discussion and  
future perspectives**

This thesis on the ageing shoulder tries to clarify some domains in the diagnosis and treatment of several degenerative shoulder conditions. The population of older patients with degeneration-related shoulder issues is not only growing but also remaining active. As a result, demands are rising as these patients refuse to exchange their active lifestyle for pain and disability.

Physicians are still challenged by patients with pain in the shoulder, with its complex anatomical architecture. The first step is making note of the medical history. Next, a variety of physical tests can help assess the shoulder in trying to identify a single anatomical structure, although their validity and usefulness is not always proven.<sup>1</sup> Usually a combination of tests increases sensitivity and specificity, hence additional imaging aids proper diagnosis. After diagnosing, clinicians attempt to understand the distorted biomechanics of the shoulder, for example after a rotator cuff tear (RCT).<sup>2-3</sup> Accordingly, this thesis sheds light on some aspects of treating shoulder patients. These aspects of the ageing shoulder joint are discussed based on the three main topics presented earlier.

### Part 1. Ageing of the acromioclavicular joint

It is clinically difficult to distinguish between a symptomatic and an asymptomatic AC joint. Sometimes the diagnosis of symptomatic AC osteoarthritis is missed or the symptoms of symptomatic AC osteoarthritis are unclear due to other degenerative shoulder conditions. We therefore studied which characteristics of AC joint osteoarthritis on MRI are correlated to clinical findings, to help clinicians in decision-making. **Chapter 3** shows that bone edema, inferior joint distension, and impression on the supraspinatus muscle on MRI scan of the shoulder are radiographic signs that have good distinctiveness. This may help differentiate from other conditions. Because symptoms of shoulder conditions generally overlap and AC osteoarthritis also causes subacromial radiating pain, it can be difficult to choose the right treatment for either the cause of complaints or other incidental findings.<sup>4</sup> Second, as degenerative conditions increase in frequency as we age, the strong association between RCTs and AC joint osteoarthritis should not be surprising.<sup>5,6</sup> However, this association does not imply causation.<sup>7</sup> Some surgeons do a distal clavicle resection when a rotator cuff repair is performed, out of habit or just “because it’s there”.<sup>8</sup> But this habit is not supported by literature,<sup>5</sup> therefore proper diagnostics are needed to further specify the cause of pain and offer the correct treatment for each patient. Future studies should define which patient, clinical and radiological characteristics are correlated to the outcome of a distal clavicle resection. Other pathological findings, such as found in an ageing rotator cuff, can present with the same clinical picture.

## Part 2. Ageing of the rotator cuff

As pointed out in **Chapter 2**, the biceps tendon is a vestigial structure whose full function is still unraveled, especially in RCTs. Some theories have been proposed as to why the biceps tendon may give rise to complaints. The hourglass theory presumes the tendon deforms as it is the remaining structure between the humeral head and the acromion when the rotator cuff is torn, leading to entrapment and pain.<sup>9</sup> Others have proposed that the painful biceps tendon is caused by overload of the long head of biceps tendon (LHBT) as it turns into a humeral head depressor in shoulders with an RCT.<sup>10</sup> Earlier experiments on the shoulder using EMG and focusing on the biceps tendon have either used a non-clinical setting or were more of a static nature. They showed hyperactivity of the biceps tendon, but this was either in patients with massive RCTs or when comparing results to healthy controls.<sup>11</sup> Our novel approach of combining a testing environment (FIT-HaNSA protocol) with registration of EMG comparing age-matched healthy controls with patients with an RCT has yielded some new insights into the function of the tendons and muscles around the shoulder. Especially the posterior deltoid muscle (PD) and biceps muscle were activated. The normal function of the PD is extension and external rotation of the arm. We assume that in an RCT the PD tries to support external rotation of the arm when the external rotation function of the rotator cuff is insufficient. Also, the PD might create a counterforce to the anterosuperior translation of the humeral head, encountered in rotator cuff-deficient shoulders. As a downside, the hyperactivity may contribute to the proximal migration of the humeral head, leading to cuff tear arthropathy. Surprisingly, the PD shows no overactivity in the downward phase, so when the arm goes down the PD stops the overactivation, the glenohumeral joint becomes unstable, and the arm drops. We think this may contribute to the dropping-arm phenomenon that is often seen in MRCTs.

In **Chapter 4** we suggest that the biceps muscle can potentially compensate for inadequate rotator cuff function. This increasing activity could lead to enlargement of the tendon and cause deterioration of the bicipital gliding mechanism. Based on the outcome of this study it remains debatable whether the hyperactivity reduces or increases pain in the shoulder. Further research is needed on whether it is beneficial to keep the biceps tendon intact when performing rotator cuff surgery. It is of interest whether selective physiotherapeutic training of the biceps and PD muscles is beneficial. EMG studies on patients with symptomatic and asymptomatic RCTs are needed to see if the same muscle patterns can be identified. If the same patterns are seen or even more activity, subsequent selective training might be of added value. Whether the torn rotator cuff leads to shoulder pain or whether shoulder pain is caused by compensatory mechanisms is a point of discussion. Additionally, it would be interesting to study compensatory mechanisms in patients with subacromial pain syndrome but no rotator cuff tear. Perhaps the hyperactivity of the PD and the biceps muscle are each also

encountered in patients with a subacromial pain syndrome. On a biological level, which structure induces the pain is also debatable: the torn rotator cuff tendon, the bursa, the LHBT, the secondary instability with superior translation? Future research should focus on the differences in muscle activation, co-activation, adaptation, kinematics and instability in patients with symptomatic RCTs compared to patients with asymptomatic RCTs and patients with subacromial pain syndrome and an intact rotator cuff. It remains interesting that not all patients with RCTs have pain.

The biceps muscle in humans has one tendon running intra-articular, and its function, use and influence are subject of heavy debate.<sup>12</sup> Due to the many structures involved in shoulder movement it is also difficult to clinically assess each structure separately, and clinical tests can detect the separate origins of pain or dysfunction only partially.<sup>1</sup> Our retrospective study on arthroscopic isolated LHBT tenotomy, presented in **Chapter 5**, shows some potential benefits for elderly patients with an RCT who do not respond to conservative measures when other, more invasive surgeries are not suitable. First, this is relatively simple minimally invasive surgery that results in pain relief, hence it seems suitable only for patients without advanced proximal migration (acromiohumeral distance >10mm). Innovations are emerging, such as a nanoscope (Arthrex), which can be used for in-office diagnostic arthroscopic inspection of the joint.<sup>13</sup> A recent study reported on its use for tenotomizing the LHBT as an outpatient clinic procedure under local anesthesia.<sup>14</sup>

The rotator cable has a protective function when there is a tear in the rotator cuff.<sup>15,16,17</sup> When the tear is past the cable, further deterioration of the shoulder function is often seen as compensatory mechanisms are insufficient.<sup>18</sup> The biceps is often tenotomized concomitant with rotator cuff repair. Couldn't the remnant of the LHBT be used for a repair of the MRCTs? Other joint-sparing treatments are available as well, such as latissimus dorsi transfer, superior capsular reconstruction and spacer balloons. They all have their learning curve and variable outcomes. A novel technique was therefore developed and presented in **Chapter 7**: using the biceps tendon as a new rotator cable to treat a MRCT. As shown in **Chapter 6**, a thorough literature search was conducted, evidencing that the biceps tendon can be successfully used for augmentation of the rotator cuff during a repair, although no one used it to restore a rotator cable, thus denying its unique function. A novel technique was therefore developed and presented in Chapter 7: using the biceps tendon as a new rotator cable to treat a MRCT.

Based on literature and after thorough cadaveric testing a small clinical pilot study was conducted. Four patients were prospectively followed; unfortunately it became clear that the technique failed in all patients. The degenerated biceps tendon did not heal and was torn at final follow-up. Still, theoretically it should be worthwhile to reconstruct the cable but perhaps by using the biceps tendon in a longitudinal fashion, or with

synthetic grafts or other implants that offer structural as well as biological support. In the end, treatment of patients with a MRCT remains challenging.

### Part 3. Trends and controversies in the treatment of the ageing shoulder

Over the years new insights have shown that there is no benefit of surgical treatment for subacromial pain syndrome. One of the most performed orthopedic surgeries is the acromioplasty, developed by Charles Neer; it implied an “impingement” of bone on tendons which needed to be relieved.<sup>19</sup> Nowadays subacromial decompression is not considered beneficial and should be reserved only for patients with very persistent pain and loss of function. Studies show also that the procedure has no additional benefit in rotator cuff repair either.<sup>20</sup> After publication of the Dutch guideline we evaluated national trends in performed shoulder surgery as reported in **Chapter 9**. We observed a decrease in the numbers of subacromial decompressions performed over the years. This change may be attributed to the guideline or to the emerging literature in general, which increasingly showed no benefit of acromioplasty compared to sham surgery or nonoperative treatment.<sup>21</sup> But even with strong scientific support, changes in clinical decision-making in daily clinical orthopedic practice is a complex issue. Several explicit and unconscious cultural and normative factors play a significant role in the daily practice of orthopedic surgery. All these factors are integrated and analyzed in a Pillar Integration Process with a thematic analysis.<sup>22</sup> Surgeons and orthopedic departments should develop an awareness of who and what is influencing their clinical decisions. The combination of all those factors results in widespread variability in surgical practices. Although formal codified knowledge in the form of clinical guidelines appears to play a modest part in orthopedic clinical decisions, the coincidence of new high-level scientific evidence by well-designed and performed RCTs and the development of clinical guidelines will have an impact on the decision-making.<sup>23</sup> We observed this effect in our study period after implementation of our clinical guideline and the publication of several clinical trials that confirmed the conclusions.

#### Clinical relevance of findings

To conclude, the aim of this thesis was: “to study the functional and radiological changes that occur in the ageing shoulder and to assess operative treatment options for certain age-related pathologies”. Although several questions remain unanswered, based on the outcomes of the studies presented in this thesis a few recommendations for general orthopedic surgeons can be made:

- MRI can be of added value to evaluate whether a degenerative AC joint is symptomatic.
- In patients with a symptomatic RCT, the posterior deltoid and the biceps muscle can be overactivated.

- If conservative treatment fails, arthroscopic isolated LHBT tenotomy can be a successful surgical option in patients with a degenerative RCT when sufficient acromial humeral distance is present.
- The LHBT can be used as an augmentation in rotator cuff repair.
- Reconstruction of the rotator cable with an LHBT autograft in patients with a MRCT does not yield clinical improvement.
- Subacromial decompression is not of added value in most patients with subacromial pain syndrome.
- We observed that after implementation of the Dutch clinical guideline for diagnosis and treatment of subacromial pain syndrome, and the publication of several clinical trials, the number of subacromial decompressions dropped significantly in the Netherlands
- So far no consensus is achieved on the best treatment for degenerative RCTs.

### Future research themes

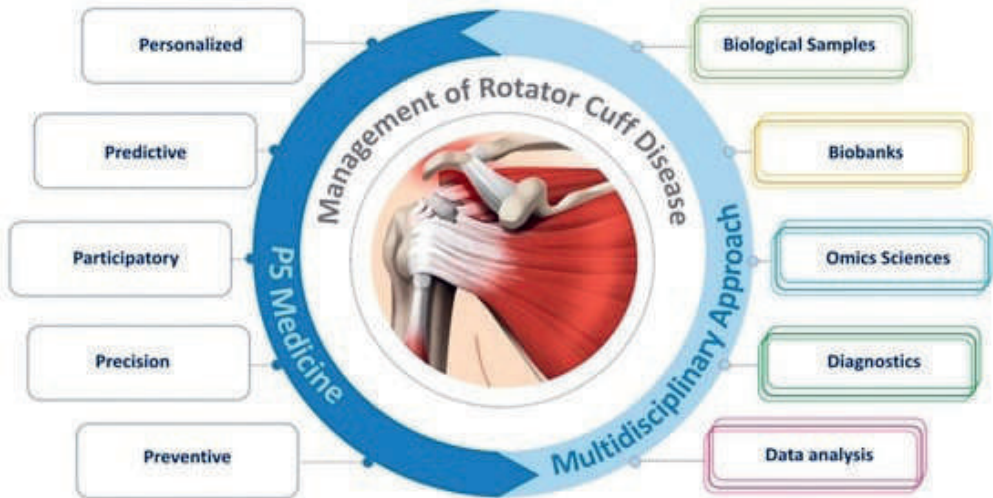
As described in this thesis, some domains in research on the ageing shoulder deserve more attention. An overview of current scientific challenges on rotator cuff-related research is presented by Longo et al.,<sup>24</sup> who insightfully categorize it into five “P” categories: Personalized, Predictive, Participatory, Precision, and Preventive Medicine. The authors propose a multidisciplinary approach (as shown in Figure 1), including several closely related topics. Some of these topics are highly applicable to further studies based on the outcome of this thesis as well, and will therefore be discussed in detail.

**Predictive:** MRI studies are needed to further specify which characteristics can predict surgical outcome, and further advances of MRI-techniques may lead to automated segmentation of shoulder muscle to measure strength and volume in new ways. This can help to preoperatively identify the “winners” after rotator cuff repair.<sup>25</sup> Many factors of influence are researched,<sup>26,27</sup> but to date no treatment algorithm exists to deliver **personalized** medicine. Big data needs to be used to develop treatment protocols to provide more accurate and **precise** shoulder care, as current published studies are based on small patient numbers (**data analysis**).

As a resultant of our **diagnostics** study (**Chapter 3**) on the use of MRI for AC osteoarthritis, it is of interest whether bone edema and inferior joint distension, and impingement on the supraspinatus tendon on MRI, are correlated with clinical outcome after distal clavicle resection.

Can preoperative testing provide guidance on who will benefit from surgery? EMG examination during the combined FIT-HaNSA testing might point toward treatment

options. Future studies, based on our developed protocol, should include different groups of shoulder patients such as symptomatic versus asymptomatic RCTs, and patients with subacromial pain syndrome versus controls. These kinds of studies would be of great interest – they may show whether the posterior deltoid and biceps muscles display hyperactivity in these groups too. Subsequently, it may help **preventively** to train these structures with a physiotherapist and see if this helps in the treatment of symptomatic patients.



**Figure 1.** Different topics and approaches for management of rotator cuff disease, *Longo et al*<sup>24</sup>

Other ways to identify the different structures that may give rise to pain can be deployed, such as selective activation (nerve stimulus) or deactivation (botox) to further understand function. Advanced imaging, such as 3D ultrasound or real-life MRI, might be available in the future. These techniques can be of value to quantify and qualify activation of muscles while performing different tests.

When the (degenerative) rotator cuff is repaired, a re-tear rate up to 50% is seen after 10 years.<sup>28</sup> Interestingly, some patients do well even after failed rotator cuff repair. This high re-tear percentage means improvement is needed, which can be found by offering **biologics** (growth factors, patches)<sup>29</sup> or mechanical strength (sutures, single vs double row, structural grafts).<sup>30</sup> There are many studies on additives but so far none is clearly outperforming others in leading to significant clinical improvement. Further knowledge on a microscopic level may help identify all different factors that contribute to rotator cuff healing and to what extent. This can be done either with **biological sampling** or even on a genetic level in **omics sciences**.

In conclusion, further assessment and profound understanding of factors of influence on the success of treatment for patients with degenerative shoulder pain is needed. Looking ahead, artificial intelligence and machine learning may be of assistance to further define the appropriate treatment for the individual patient, leading to personalized medicine.



## REFERENCES

1. Gismervik SØ, Drogset JO, Granviken F, Rø M & Leivseth G (2017). Physical examination tests of the shoulder: a systematic review and meta-analysis of diagnostic test performance. *BMC musculoskeletal disorders*, 18(1), 1-9.
2. Collin P, Matsumura N, Lädermann A, Denard PJ & Walch G (2014). Relationship between massive chronic rotator cuff tear pattern and loss of active shoulder range of motion. *Journal of shoulder and elbow surgery*, 23(8), 1195-1202.
3. Lädermann A, Denard PJ, & Collin P (2015). Massive rotator cuff tears: definition and treatment. *International orthopaedics*, 39(12), 2403-2414
4. Mall NA, Foley E, Chalmers PN, Cole BJ, Romeo AA, & Bach Jr, BR (2013). Degenerative joint disease of the acromioclavicular joint: a review. *The American journal of sports medicine*, 41(11), 2684-2692.
5. Wang J, Ma JX, Zhu SW, Jia HB & Ma XL (2018). Does distal clavicle resection decrease pain or improve shoulder function in patients with acromioclavicular joint arthritis and rotator cuff tears? A meta-analysis. *Clinical orthopaedics and related research*, 476(12), 2402.
6. Matsen III FA (2018). CORR Insights®: Does Distal Clavicle Resection Decrease Pain or Improve Shoulder Function in Patients With Acromioclavicular Joint Arthritis and Rotator Cuff Tears? A Meta-analysis. *Clinical orthopaedics and related research*, 476(12), 2415.
7. Hill, AB (1965 Jan). "The environment and disease: association or causation?." *Proceedings of the Royal Society of Medicine* vol. 58(5): 295-300.
8. Neviasser TJ, Neviasser RJ & Neviasser JS (1982). The four-in-one arthroplasty for the painful arc syndrome. *Clinical orthopaedics and related research*, (163), 107-112.
9. Boileau P, Ahrens PM & Hatzidakis AM (2004). Entrapment of the long head of the biceps tendon: the hourglass biceps—a cause of pain and locking of the shoulder. *Journal of shoulder and elbow surgery*, 13(3), 249-257.
10. Kido, T., Itoi, E., Konno, N., Sano, A., Urayama, M., & Sato, K. (2000). The depressor function of biceps on the head of the humerus in shoulders with tears of the rotator cuff. *The Journal of bone and joint surgery. British volume*, 82(3), 416-419.
11. Spall P, Ribeiro DC & Sole G (2016). Electromyographic activity of shoulder girdle muscles in patients with symptomatic and asymptomatic rotator cuff tears: a systematic review and meta-analysis. *PM&R*, 8(9), 894-906.
12. Sakurai G, Ozaki J, Tomita Y, Nakagawa Y, Kondo T & Tamai S (1998). Morphologic changes in long head of biceps brachii in rotator cuff dysfunction. *Journal of orthopaedic science*, 3(3), 137-142.
13. Peach C, Davies R & Phillips N (2021). Wide-Awake Shoulder Nanoscopic Long Head of Biceps Tenotomy. *Arthroscopy techniques*, 10(3), e909-e912.
14. Gauci MO, Monin B, Rudel A, Blasco L, Bige B, & Boileau P (2021). In-Office Biceps Tenotomy with Needle Arthroscopy: A Feasibility Study. *Arthroscopy Techniques*, 10(5), e1263-e1268.
15. Burkhart SS, Esch JC & Jolson RS (1993). The rotator crescent and rotator cable: an anatomic description of the shoulder's "suspension bridge". *Arthroscopy: The Journal of Arthroscopic & Related Surgery*, 9(6), 611-616.
16. Rahu M, Kolts I, Põldoja E & Kask K (2017). Rotator cuff tendon connections with the rotator cable. *Knee Surgery, Sports Traumatology, Arthroscopy*, 25(7), 2047-2050.
17. Huri G, Kaymakoglu M, & Garbis N (2019). Rotator cable and rotator interval: anatomy, biomechanics and clinical importance. *EFORT open reviews*, 4(2), 56-62
18. Wang L, Kang Y, Xie G, Cai J, Chen CA, Yan X, ... & Zhao, J. (2021). Incomplete rotator cable did not cause rotator cuff dysfunction in case of rotator cuff tear: a biomechanical study of the relationship between rotator cable integrity and rotator cuff function. *Arthroscopy: The Journal of Arthroscopic & Related Surgery*, 37(8), 2444-2451.

19. Neer CS 2nd (1972) Anterior acromioplasty for the chronic impingement syndrome in the shoulder: a preliminary report. *J Bone Joint Surg Am.*, Jan 54(1):41-50.
20. Jarvis DL, Waterman BR, Verma NN (2019). Is Acromioplasty Ever Indicated During Rotator Cuff Repair? *Arthroscopy*, Jun 35(6):1639-1640.
21. Beard DJ, Rees JL, Cook JA, Rombach I, Cooper C, Merritt N et al. (2018). Arthroscopic subacromial decompression for subacromial shoulder pain (CSAW): a multicentre, pragmatic, parallel group, placebo-controlled, three-group, randomised surgical trial. *The Lancet*, 391(10118), 329-338.
22. Johnson RE, Grove AL & Clarke A (2019). Pillar integration process: A joint display technique to integrate data in mixed methods research. *Journal of Mixed Methods Research*, 13(3), 301-320.
23. Khan H, Hussain N & Bhandari M (2013). The influence of large clinical trials in orthopedic trauma: Do they change practice? *J Orthop Trauma*, 27(12): e274.
24. Longo UG, Carnevale A, Massaroni C, Lo Presti D, Berton A, Candela V et al. (2021). Personalized, Predictive, Participatory, Precision, and Preventive (P5) Medicine in Rotator Cuff Tears. *Journal of Personalized Medicine*, 11(4), 255.
25. Jeong HY, Kim HJ, Jeon YS & Rhee YG (2018). Factors predictive of healing in large rotator cuff tears: Is it possible to predict retear preoperatively?. *The American journal of sports medicine*, 46(7), 1693-1700.
26. Keener JD, Patterson BM, Orvets N, Chamberlain AM. (2019) Degenerative Rotator Cuff Tears: Refining Surgical Indications Based on Natural History Data. *J Am Acad Orthop Surg*, 27(5):156-165.
27. Lambers Heerspink FO & Dorrestijn O (2020). Editorial Commentary: Rotator Cuff Tear: Know When Not to Operate So You Don't Make It Worse. *Arthroscopy* 36(8): 2091-2093.
28. Randelli PS, Menon A, Nocerino E, Aliprandi A, Feroldi FM, Mazzoleni MG et al. (2019) Long-term Results of Arthroscopic Rotator Cuff Repair: Initial Tear Size Matters: A Prospective Study on Clinical and Radiological Results at a Minimum Follow-up of 10 Years. *The American Journal of Sports Medicine*, 47(11): 2659-2669.
29. Thon SG, O'Malley L, O'Brien MJ & Savoie III FH (2019). Evaluation of healing rates and safety with a bioinductive collagen patch for large and massive rotator cuff tears: 2-year safety and clinical outcomes. *The American journal of sports medicine*, 47(8), 1901-1908.
30. Plachel F, Siegert P, Rüttershoff K, Thiele K, Akgün D, Moroder P, Scheibel M, Gerhardt C. (2020) Long-term Results of Arthroscopic Rotator Cuff Repair: A Follow-up Study Comparing Single-Row Versus Double-Row Fixation Techniques. *The American Journal of Sports Medicine*, 48(7):1568-1574.





**Summary**

**Nederlandse samenvatting**

## SUMMARY

Due to its unique anatomy and biomechanics, the shoulder shows some distinctive patterns while ageing. Several controversies are ongoing in the field of imaging, clinical testing, and existing and trending treatments for ageing patients with shoulder pain. This thesis attempted to shed some light on these topics.

### Part 1 Ageing of the acromioclavicular joint

Part 1 identifies signs of the degenerating acromioclavicular joint. This is one of the joints composing the shoulder; it is often arthritic but not always symptomatic. By comparing MRI scans of patients with symptomatic AC osteoarthritis to a cohort of patients with subacromial pain syndrome (SAPS) and without clinical signs of AC osteoarthritis, we were able to identify several predictive findings. The presence of inferior osteophytes, bone marrow edema, impression on the supraspinatus, and inferior joint distension was individually associated with symptomatic AC osteoarthritis. The results presented in **Chapter 3** can help in clinical decision-making: they are practical and easy to use, and can assist the physician in diagnosing symptomatic AC osteoarthritis.

### Part 2. Ageing of the rotator cuff: functional analysis and evaluation of established and novel surgical techniques

Part 2 is about the rotator cuff, with several studies focusing on functional analysis and evaluation of established and novel surgical techniques. The rotator cuff is one of the shoulder structures most prone to degeneration in elderly patients. Although not always symptomatic, rotator cuff tears (RCTs) are seen in up to 40% of elderly patients. Interestingly, patients are able to move their arm, which means that other muscle and tendon can compensate for a torn tendon. In **Chapter 4** we assessed patients and controls by time, video and electromyography (EMG) while they performed activities of daily living (Functional Impairment Test-Hand and Neck/Shoulder/Arm (FIT-HaNSA)). Patients with a symptomatic rotator cuff tear show compensatory movement patterns based on abnormal hyperactivity of the biceps brachii and posterior deltoid muscles when compared with age-matched controls. The posterior deltoid functions less in conjunction with the other parts of the deltoid muscle, and lower coactivation was seen in the remaining intact rotator cuff muscles in the rotator cuff tear group than in the control group. This study supports the potential benefit of addressing the long head of biceps tendon (LHBT) in the treatment of patients with a symptomatic rotator cuff tear.

When treating patients with a rotator cuff tear a direct repair is not always possible. This depends on several factors. When conservative treatment fails, one easy-to-perform surgery is an isolated arthroscopic tenotomy of the LHBT. In **Chapter 5** our case series, involving 64 patients aged 65 and older with a degenerative RCT, shows that this treatment is successful for reducing pain and gaining function in a selected population.

The procedure is often part of other arthroscopic shoulder surgery, but so far has not been described as an isolated treatment.

Many surgical techniques are available for a massive RCT. **Chapter 6** provides a systematic review of the use of the LHBT as an autograft to augment repair in the treatment of RCTs. Eight case series were identified, all showing different techniques for harvesting and augmentation of the LHBT. The clinical results of these studies evidenced significantly improved function, pain relief and range of motion at follow-up, although this was not compared with a control group. The tendon constructs were intact on MRI in most patients (82%) within two years. This shows that use of a biceps autograft is an option for augmentation in massive RCTs, although given the variable quality of the studies no definitive recommendations can be offered.

Based on the results from Chapter 6, in **Chapter 7** we subsequently propose a novel technique of using the LHBT to reconstruct the rotator cable. This rotator cable, a transverse tendon-like structure in the rotator cuff which distributes the forces, is often involved in massive RCTs. It can be restored by incorporating the LHBT as a new cable. This study supplies a step-by-step guide, including several images. In **Chapter 8** this new technique of using the LHBT as an autograft for reconstruction of the rotator cable is evaluated in a pilot study involving four patients, average age 64, with an irreparable MRCT. After surgery most of the patients showed significant improvement on the clinical outcome scores, albeit with disintegration of the cable on MRI at 12 months follow-up.

### Part 3. Trends and controversies in the treatment of the ageing shoulder

Part 3 gives an overview of trends in treatments for the ageing shoulder as well as their controversies. In 2014 the Dutch Orthopedic Society established a clinical practice guideline for the diagnosis and treatment of subacromial pain syndrome (SAPS). In **Chapter 9** we evaluate the effects of this guideline on the current practice of general practitioners and orthopedic surgeons in the Netherlands. Trends in the conservative and operative treatment of SAPS and RCTs are studied by analyzing the Diagnosis Related Groupings declared by all Dutch hospitals. From 2012 to 2016 fewer patients were diagnosed with SAPS and a 5% drop in subsequent surgical treatment was seen. By contrast, more patients were diagnosed with an RCT but fewer were treated surgically over the years. As the results of this study show, controversies remain among orthopedic surgeons as to the ideal treatment for degenerative RCTs.

To further display international opinions on the treatment of RCTs, in **Chapter 10** we present current literature as a *pro et contra* of rotator cuff tear surgery. Many studies are available and a scoping overview is given. The thesis ends with a general discussion in **Chapter 11**, offering future perspectives on shoulder-related research.

## NEDERLANDSE SAMENVATTING

### Proefschrift: The ageing shoulder: imaging, functional assessment and arthroscopic interventions

Als gevolg van zijn unieke anatomische en biomechanische aspecten laat het schoudergewricht een aantal typische verouderingspatronen zien. Omdat de westerse mens actief blijft tot op hogere leeftijd, stelt deze ook meer eisen aan de lichamelijke functionaliteit van het schoudergewricht. Rondom de behandeling van de oudere patiënt met schouderklachten zijn er nog altijd controverses op het gebied van beeldvorming, klinische testen en nieuwe behandeltechnieken. Deze thesis probeert meer helderheid te verschaffen op deze gebieden.

#### Deel 1: Het verouderende acromioclaviculaire gewricht

Deel 1 onderzoekt tekenen van het verouderen van het acromioclaviculaire gewricht (AC-gewricht). Het AC-gewricht is het gewricht tussen het sleutelbeen en het schouderblad en 1 van de 4 gewrichten die deel uitmaken van de schouder. Dit gewricht vertoont vaak slijtage (artrose), maar dat hoeft lang niet altijd klachten te geven. Om dit te onderzoeken, hebben we een groep patiënten met klinische klachten van het AC-gewricht vergeleken met een groep patiënten zonder klinische klachten van het AC-gewricht maar met andere schouderklachten, bijvoorbeeld het subacromiaal pijn syndroom. De MRI-scans van beide groepen hebben we vergeleken en we hebben meerdere kenmerken gevonden die voorspellend zijn voor klachten van het AC-gewricht. Botaangroei rond het AC-gewricht, vocht in de mergholte van het sleutelbeen, indeuking in de rotator-cuff-pees en een opbollend gewrichtskapsel worden elk afzonderlijk geassocieerd met klachten van AC-artrose. De resultaten van **Hoofdstuk 3** kunnen helpen bij klinische besluitvorming. De beschreven kenmerken zijn makkelijk te identificeren op een MRI en daarmee bruikbaar voor het diagnosticeren van symptomatische AC-artrose.

#### Deel 2: de verouderende rotator-cuff: functionele analyse en evaluatie van bestaande én nieuwe chirurgische technieken.

De rotator-cuff is een peesblad dat rond de schouder ligt, aan de binnenzijde vastzit aan 4 schouderpijpen en aanhecht op de schouderkop aan de buitenzijde. Samen zorgen ze ervoor dat de schouderkop bij elke beweging centraal in de kom blijft. Hierdoor is er een ruime bewegelijkheid van de schouder. De rotator-cuff is 1 van de structuren van de schouder die regelmatig tekenen van slijtage laten zien bij het ouder worden. Tot wel 40 procent van de 60-plussers heeft scheuren in deze pezen. Dit hoeft alleen lang niet altijd klachten te geven. Bij patiënten met een gescheurde pees is het fascinerend om te zien dat ze hun arm kunnen bewegen, doordat andere spieren en pezen kunnen compenseren voor het functieverlies van de gescheurde pees. Deel 2 van dit proefschrift



bestaat uit meerdere studies die de functie van de rotator-cuff analyseren en bestaande én nieuwe chirurgische technieken evalueren.

**Hoofdstuk 4** analyseert de schouderbewegingen van patiënten met een rotator-cuff-scheur en vergelijkt deze gegevens met die van gezonde vrijwilligers, die even oud zijn en geen rotator-cuff-scheur hebben. Beide groepen hebben oefeningen uitgevoerd die gebaseerd zijn op dagelijkse activiteiten. Dit volgens de Functional Impairment Test-Hand and Neck/Shoulder/Arm (FIT-HaNSA). Dit moet gebeuren binnen een bepaalde tijd, waarbij de bewegingen met video en spieractiviteit met electromyografie worden gemeten. De groep patiënten met een rotator-cuff-scheur laat compenserende bewegingspatronen zien in vergelijking met de gezonde controlegroep van dezelfde leeftijd. De bicepsspier of tweehoofdige bovenarmspier en het achterste gedeelte van de deltaspier zijn opvallend actief bij de patiënten met een rotator-cuff-scheur. Bij de patiënten met een rotator-cuff-scheur werkt het achterste gedeelte van de deltaspier minder goed samen met de andere delen. Daarnaast werken de gedeelten van de rotator-cuff-spiers die nog intact zijn minder goed samen. Deze studie bevestigt dat het mogelijk kan helpen om de lange bicepspees te behandelen bij patiënten met klachten van een rotator-cuff-scheur.

Een rotator-cuff-scheur rechtstreeks hechten op het bot is niet altijd mogelijk. Dit is afhankelijk van meerdere factoren. Als de niet-operatieve behandeling niet effectief is en de scheur niet gehecht kan worden, wordt soms de lange bicepspees gekliefd tijdens een kijkoperatie: arthroscopie. Deze eenvoudige behandeling wordt vaak uitgevoerd als onderdeel van arthroscopische schouderoperaties. Het is alleen nog niet beschreven als solitaire ingreep. In **Hoofdstuk 5** presenteren we een groep van 64 patiënten van 65 jaar en ouder met een rotator-cuff-scheur, die zijn behandeld met deze techniek. Na de operatie zijn er minder pijnklachten en neemt de functie toe bij de meerderheid van de patiënten.

Er bestaan vele chirurgische technieken voor de behandeling van een massale rotator-cuff-scheur. **Hoofdstuk 6** beschrijft systematisch het gebruik van de lange bicepspees als transplantaat om als versterking te gebruiken bij het hechten van een gescheurde rotator-cuff-scheur aan de humeruskop. Uiteindelijk hebben we 8 onderzoeken gevonden en allen beschrijven een verschillende techniek voor het verkrijgen en daarna gebruiken van de lange bicepspees als versterking. De klinische resultaten van deze studies laten allen een significante verbetering zien van functie, afname van pijn en toename van bewegelijkheid. Deze studies vergelijken deze resultaten alleen niet met een controlegroep. Bij 82 procent van de patiënten van deze studies zijn de peesreconstructies intact bij MRI-onderzoek binnen 2 jaar. Dit laat zien dat een bicepspees gebruiken als versterking een goede optie kan zijn bij de operatieve

behandeling van massale rotator-cuff-scheuren. We kunnen alleen geen definitieve aanbevelingen geven vanwege de wisselende kwaliteit van de studies.

Wegens de resultaten beschreven in **Hoofdstuk 6**, hebben we een nieuwe chirurgische techniek ontwikkeld. Hierbij gebruiken we de bicepspees voor reconstructie van de 'rotatorkabel', die **Hoofdstuk 7** beschrijft. Deze rotatorkabel is een natuurlijke versterking van de rotator-cuff en is vaak aangedaan in het geval van een massale rotator-cuff-scheur. Dit kan hersteld worden door de lange bicepspees te gebruiken als nieuwe rotatorkabel. In deze studie beschrijven we met foto's en een video deze nieuwe operatietechniek stap voor stap. In **Hoofdstuk 8** evalueren we de nieuwe techniek, waarbij we de lange bicepspees gebruiken als een transplantaat om de rotatorkabel te reconstrueren. Deze pilotstudie bestaat uit 4 patiënten van gemiddeld 64 jaar oud met een niet te repareren, massale rotator-cuff-scheur. Na 12 maanden lieten de meeste patiënten een significante verbetering zien op de klinische uitkomstscores, maar was er sprake van desintegratie van de gereconstrueerde kabel op de MRI. Deze nieuwe techniek laat vooralsnog geen voordelen zien boven beschreven technieken uit genoemde onderzoeken in **Hoofdstuk 6**. Nader onderzoek is gewenst.

### Deel 3. Trends en tegenstrijdigheden bij de behandeling van de verouderende schouder

Deel 3 geeft een overzicht van trends in behandelingen van de verouderende schouder. Daarnaast diepen we een aantal controverses uit, zoals het wel of niet chirurgisch behandelen van een rotator-cuff-scheur. In 2014 heeft de Nederlandse Vereniging voor Orthopedie de richtlijn 'diagnose en behandeling van het subacromiaal pijnsyndroom (SAPS)' uitgebracht. SAPS is een symptomatische diagnose en een veel voorkomende oorzaak van pijn in de schouder bij volwassenen. Ieder jaar krijgen ongeveer 2 van de 100 volwassenen in Nederland last van deze schouderklachten. Bij patiënten met SAPS doet vooral het optillen van de arm pijn. Later is de schouder ook in rust pijnlijk. De pijn komt voort uit een veroudering, overbelasting of beschadiging van de pezen of spieren rondom het schoudergewricht. **Hoofdstuk 9** onderzoekt het effect van deze richtlijn op het handelen van orthopedisch chirurgen en huisartsen in Nederland. Door alle gedeclareerde diagnose-behandelcombinatie (DBC's) van de Nederlandse ziekenhuizen te analyseren, zijn er trends te zien in de operatieve en niet-operatieve behandeling van SAPS en rotator-cuff-scheuren. Van 2012 tot 2016 is de diagnose SAPS steeds minder vaak gesteld door orthopeden en is er een afname van 5% in operatieve behandelingen hiervan. Daarentegen worden er meer patiënten met een rotator-cuff-scheur gediagnosticeerd, maar over de jaren wordt steeds minder vaak een operatie uitgevoerd. Zoals de resultaten van deze studie laten zien, blijven er controverses bij de behandeling van degeneratieve rotator-cuff-scheuren. Dit is ook te zien in de wetenschappelijk literatuur. Daarom geeft **Hoofdstuk 10** een overzicht van

de huidige stand van de wetenschap als een *pro et contra* van rotator-cuff-operaties. Op dit onderwerp zijn vele studies verricht, waarbij nog geen eenduidig antwoord is over de meerwaarde van chirurgische behandeling en welke factoren van invloed zijn op genezing. Daarnaast is een alomvattende samenvatting gemaakt. De thesis eindigt met een algemene discussie die suggesties geeft over nog te verrichten onderzoek van schouderklachten bij ouderen.



**Dankwoord**

**About the author**

**Publications and presentations**

**Research Institute SHARE**

## DANKWOORD

Dit proefschrift is tot stand gekomen ten tijde van mijn opleiding tot orthopedisch chirurg. Dit zorgde soms voor conflicterende belangen als het gaat om tijdsbesteding, maar ik heb het vooral als een verrijking gezien. Het is een open deur om te stellen dat je alleen sneller bent, maar samen verder kunt komen. Ik heb dit proefschrift nooit alleen kunnen volbrengen. Daarom wil ik een aantal personen in het bijzonder bedanken voor hun hulp bij het volbrengen van dit promotietraject.

Ten eerste wil ik alle betrokken patiënten bedanken voor hun inzet, tijd en bereidwilligheid om te participeren en hun gegevens te delen voor de verschillende onderzoeken. Zonder jullie was dit proefschrift niet mogelijk geweest. Bedankt voor het steunen van de wetenschap!

Prof. Dr. R.L. Diercks, beste Ron, schoorvoetend heb ik je in 2014 benaderd voor schouder onderzoek. Ik was enthousiast geworden over het schoudergewricht door mijn ANIOS-tijd in het Deventer Ziekenhuis. Samen hebben we meerdere creatieve brainstorm sessies gehad en een aantal lijnen kunnen uitzetten. In het begin beschouwde ik dit traject als het 'onderzoek voor erbij' maar in de loop van de tijd kreeg het dankzij jouw enthousiasme steeds meer de vorm van een promotie. Ik heb bewondering voor je scherpe en meestal 'out-of-the-box' ideeën. Dankzij jouw wetenschappelijke inzichten, die je ook nog eens perfect op schrift kan zetten, zijn de onderzoeken naar een hoger niveau getild. Bedankt voor het terugfluiten als ik te hard aan het trappelen was. Ook samen naar het ESSKA congres met de UMCG delegatie was prachtig: De 'whiskey of the month' in Glasgow smaakte ons goed.

Dr. M. Stevens, beste Martin, vanaf het begin van de promotie ben je een prettige steunpilaar om op terug te vallen. Even weer op de deur kloppen en kort wat overleggen. Met name rond de klinische studies en de toenemende registratielast wist ik weer eens niet wat ik moest doen. Je had dan altijd een creatieve oplossing die niet teveel moeite kostte. Jouw blik als bewegingswetenschapper hielp om de manuscripten begrijpelijk te houden. Het is zeer prettig samen te werken met jou. Je snelle reacties, met altijd wel een kanttekening, hielden me scherp.

Dr. C.T. Kooreveaar, beste Rinco, hoewel je pas later officieel aan boord was als co-promotor, was je direct zeer betrokken. Ik ben er trots op je eerste promovendus te zijn. Je bent een ware en zeer betrokken mentor. Elke keer als ik je spreek, merk ik hoe fijn het is om dezelfde 'schoudertaal' te spreken. Zomaar een uur bellen over schouders, maar ook over het leven daarbuiten. Ondanks dat ik niet een fellowship bij je heb kunnen doen, hoop ik dat ik je visies over de schouder heb opgepikt. Ik wens je veel plezier en (werk)geluk in Zweden.

Hooggeleerde leden van de beoordelingscommissie; prof. dr. R.G.H.H. Nelissen, prof. dr. P.C. Jutte en prof. dr. HEJ Veegher, hartelijk dank voor het lezen en beoordelen van dit proefschrift.

Wijlen Dr. A.F.W. Barnaart, beste Lex, jij hebt me destijds als ANIOS gestimuleerd om schouderonderzoek te doen: "Bart-Jan, de schouder, daar zijn de ontwikkelingen en nog veel onderzoek te doen." Een erudiete opleider met hart voor de patiënten. Je bent nog steeds een voorbeeld voor mij.

Mede-onderzoekers Deventer Ziekenhuis: Beste Ydo, Ellie, Ashvin, Lilian, Robin en Rosalie, bedankt voor de prettige samenwerking. Het laat zien dat ook een klein ziekenhuis goed in onderzoek kan zijn.

Mede-onderzoekers UMCG: Beste Johannes, Tim, Tom en Koen, bedankt voor de hulp bij het maken van de EMG's en Koen in het bijzonder voor de geavanceerde analyses. Olivier, bedankt voor het toetsen van de studie, alle fijne promotietips en het doorzakken op congressen. Roy Stewart, voor statistische ondersteuning. En dankzij jullie hulp, Els, Yvon en Stefan, kreeg ik de administratie bij alle studies rond.

Ruth Rose en Greetje den Holder, bedankt voor alle correcties op taalgebruik in het Engels en Nederlands.

Beste Buuf, Marije, bedankt voor het prachtige eigentijdse ontwerp wat losjes gebaseerd is op een albumcover van het toepasselijke 'Bicep', een van onze favoriete dj's.

De orthopedie opleidingsgroepen van het UMCG, MCL en DZ wil ik bedanken voor de gedegen opleiding, waarbij ik me al vroeg mocht specialiseren richting de schouder en sportorthopedie. Maar ook dat ik mijn onderzoekstijd en verloren uren mocht besteden aan mijn promotie.

Collega's vakgroep orthopedie MST: beste maten Elgun, Henk, Lonneke, Christiaan, Yvon, Jorm en Wiebe, bedankt voor het vertrouwen en steun bij de eindsprint van deze promotie. Fijn dat ik de ruimte krijg om mij op het schoudergebied te ontwikkelen. Op naar nog vele jaren fijne samenwerking.

Justin, wat is het prachtig dat we al sinds de jaarclubvorming samen het leven doorkruisen. Of ik nou in Groningen, Zwolle, Australië of Enschede zit, we weten elkaar altijd te vinden. Weekenden op pad zonder of juist met vrouwen en kinderen. Het maakt niet uit, want het is altijd top. Ik ben je dankbaar voor de vriendschap en vind het bijzonder dat je mijn paranifm wil zijn.

Geachte Rambo, beste Rinze, al tijdens onze co-schappen werd in huize Rambo de basis voor onze vriendschap gelegd en werden we beide direct getrokken door de chirurgische vakken. Later aan de Butjesstraat in Groningen hebben we samen aan menig studentenfiets geklutst met werkelijk de meest roestige onderdelen. Gelukkig halen we tegenwoordig kwaliteitsgereedschap bij de Lidl. Fijn dat ik je altijd om advies kan vragen en dat je mijn paranimf wil zijn.

Beste schoonouders, lieve Wiek en Nanny, dank voor alle steun, tekstuele correcties en vele oppas-uren, waardoor ik meters kon maken met het proefschrift.

Lieve Bert en Ria, pap en mam, dankzij jullie ben ik op dit punt aan gekomen. Onvoorwaardelijke steun zonder te pushen, maar wel tijdig te sturen; dank! Nu mijn kinderen zelf steeds groter worden, hoe meer ik terugdenk: "Hoe deden zij het?" Pap, hoe graag zou ik over mijn ervaringen als orthopeed met jou als vader, maar ook als fysiotherapeut willen sparren. Ik weet zeker dat je trots zou zijn. Mam, de lieve kaartjes en appjes komen altijd op het juiste moment. Lieve Tino, jij als niet-medicus kan met zeer relativerende ideeën komen. Daarnaast ben je een top-opa voor de kinderen. Vincent en Laurens, 'mien breurs', het is fijn om jullie als broers te hebben. Jullie staan altijd voor me klaar en zetten mij met beide voeten op de grond. Niets beters dan samen fysiek bezig te zijn en de bomen te zagen en kloven in Mariënberg. Oma Schipper, fijn dat ik nog wekelijks met je kan bellen over de voortgang van het proefschrift en het wel-en-wee van de familie. Je hebt een bijzonder plek in mijn hart.

Allerliefste Jens, Felix en Daantje, jullie zijn de belangrijkste en beste reden om veel langer over deze promotie te doen dan gepland. Ik hou van jullie en draag dit boek aan jullie op!

"Reis ver, drink wijn, denk na, lach hard, duik diep, kom terug." Lieve Loes, toen we dit najaar eindelijk weer eens naar een concert konden, kwam deze tekst van Spinvis zo goed overeen met het leven na ons prachtige jaar in Australië. Nu dan uiteindelijk teruggekomen in Twente. We hadden beiden niet verwacht om te eindigen op mijn geboortegrond. Samen weer een leven opbouwen en oud worden in ons fijne huis met onze 3 prachtige kinderen. Ik voel me gezegend. Bedankt voor de steun en begrip, maar vooral dat je mij op vele momenten tijdig van de laptop hebt gehaald. Er is meer in het leven dan schouders. Op naar nog vele weekenden Mariënberg, concerten, festivals, surfessies en reizen. Niet alleen muziek, maar het hele leven is beter met jou!  
*Stardust - Music sounds better with you (1998)*



## ABOUT THE AUTHOR



Bart-Jan Veen was born on the 4th of November, 1984 and was raised in the Dutch town of Wierden in a warm family with two younger brothers. He graduated from secondary school (Atheneum, CSG het Noordik, Almelo) in 2003 and started his medical training at the University of Groningen. After his training he was a medical officer (ANIOS) at the orthopedic departments of Medisch Spectrum Twente in Enschede and Deventer Hospital. In 2013 he started his general surgery training at Isala Clinics Zwolle under the supervision of Dr. Sven van Helden. His orthopedic rotations were mainly

at UMC Groningen, under the supervision of Prof. Sjoerd Bulstra. During this period he initiated his PhD trajectory under the supervision of Prof. Ron Diercks and Dr. Martin Stevens. Several research projects were continued during his regional training at Deventer Hospital under the supervision of Dr. Lex Barnaart, and Dr. Rinco Koorevaar became actively involved in the research.

In 2015 he married Loes Pameijer, and both their sons Jens (2015) and Felix (2017) were born in Groningen.

To gain more exposure in arthroscopic and knee surgery, Bart-Jan undertook a sports internship at Medical Center Leeuwarden under the supervision of Dr. Paul Rijk. In 2019 he was selected for a travelling fellowship of the Dutch Arthroscopy Society and visited several hospitals in the Netherlands and Germany.

Bart-Jan completed most of his studies in his final year of training at UMC Groningen. In 2019 he moved his family to Brisbane, Australia, for the Australian Shoulder Arthroscopy and Arthroplasty Fellowship under the supervision of Prof. Kenneth Cutbush and Prof. Ashish Gupta. During this very inspiring year he gained extensive knowledge and skills in advanced shoulder surgery and published several papers. This was a true adventure for the whole family, living and working abroad in a tropical environment with excellent surf beaches nearby.

Upon their return to the Netherlands in 2021 their daughter Daantje was born and he started a job as consultant orthopedic surgeon at Medical Spectrum Twente in Enschede. Here he is able to further specialize in shoulder, elbow and arthroscopic knee surgery. On weekends they love to go outdoors to their cottage to chop wood, pitch a fire and have family time.

## PUBLICATIONS AND PRESENTATIONS

### **Update guideline for diagnosis and treatment of subacromial pain syndrome start 2022**

Board delegate for Dutch Shoulder and Elbow Society

O. Dorrestein, R.L. Diercks, F.O. Lambers Heerspink, E.J.D. Veen

### **Consensus statement for shoulder impingement: to operate or not? Who to ask for the consensus panel?**

Letter to the editor, Arthroscopy

*Submitted*

E.J.D. Veen, E. Smits, A.M. Ker, S.L. Whitehouse, B. Ziegenfuss, A.Gupta, K. Cutbush

### **Anterior deltoid muscle refelction using a deltopectoral approach is safe and does not influence outcoume of reversed arthroplasty.**

*Submitted*

Oral presentation SECEC 2021, Poznan, Poland

Oral presentation, ISAKOS 2021, South Africa/online

S.Pinel, E.B.M. Landman, E.J.D. Veen, Y.V. Kleinlugtenbelt, C.T. Koorevaar

### **Superior clinical outcome of a rotator cuff repair compared to a long head of biceps tenotomy in elderly patients with rotator cuff tears.**

*Submitted*

E.J.D. Veen, A.M. Ker, J.C. Maharaj, K. Cutbush, A. Gupta

### **B2B: A technical note and case report on long head of biceps tendon autograft for chronic distal biceps tendon reconstruction.**

JSES Reviews, Reports, and Techniques (2021) 1 (1), 45-49

A.Gupta, A.M. Ker, J.C. Maharaj, E.J.D.Veen, K. Cutbush

### **All-Arthroscopic Muscle Slide and Advancement Technique to Repair Massive Retracted Posterosuperior Rotator Cuff Tears.**

Arthroscopy Techniques (2021) e1439-e1446

A.M. Ker, E.J.D. Veen, J.C. Maharaj, M.M. Launay, K. Cutbush, A Gupta

### **Pediced-lesser tuberosity osteotomy for glenohumeral joint exposure: a technical note and case report highlighting its use in allograft reconstruction of a large engaging reverse Hill-Sachs lesion after posterior shoulder dislocation**

JSES Reviews, Reports, and Techniques (2021) 224-228

M. Bhandari (editor)

**Evidence-Based Orthopedics 2nd edition,**

E.J.D. Veen, R.L. Diercks authors of book chapter “Subacromial Pain Syndrome”

Publisher Wiley Blackwell, EAN 9781119413943, page 739-742

E.J.D. Veen, C.T. Koorevaar, K. Verdonshot, T.E. Sluijter, T. de Groot, J.H. van der Hoeven, R.L. Diercks, M. Stevens

**In patients with symptomatic rotator cuff tears, the compensatory movement patterns are based on abnormal activity of the biceps brachii and posterior deltoid muscles.**

Clinical Orthopaedics and Related Research (2021) 479(2), 378-388

*Poster presentation SECEC e-congress 2020*

*Awarded by Share research department as “PhD Top Publication”*

E.J.D. Veen, A. V. Boeddha, R.L. Diercks, Y.V. Kleinlugtenbelt, E.B.M. Landman, C.T. Koorevaar

**Arthroscopic isolated long head of biceps tenotomy in patients with degenerative rotator cuff tears: long-term clinical results and prognostic factors.**

European Journal of Orthopedic Surgery and Traumatology (2021) 31(3), 441-448

*Poster presentation AGA Kongress 2019, Mannheim, Germany*

*Poster presentation EFORT 2019, Lisbon, Portugal*

*Poster presentation ESSKA 2021, Milan, Italy*

A. Brandsma, E.J.D. Veen, A.W.J.M. Glaudemans, P.C. Jutte, J.J.W. Ploegmakers

**Custom-made treatment for a near joint oncologic lesion; A case report of a 3-D printed prosthesis for a grade II chondrosarcoma of the proximal ulna.**

Journal of Shoulder and Elbow Surgery International (2020) 5(1), 42

E.J.D. Veen, C.T. Koorevaar

**Degenerative rotator cuff tears: to remain untouched?**

Nederlands Tijdschrift voor Orthopedie (2020) 27(1), 19-20

*invited paper*

E.J.D. Veen, R.L. Diercks, E.B.M Landman, C.T. Koorevaar

**The results of using a tendon autograft as a new rotator cable for patients with a massive rotator cuff tear: a technical note and comparative outcome analysis.**

Journal of Orthopaedic Surgery and Research (2020) 15 (1), 47

E.J.D. Veen, M. Stevens, R.L. Diercks, C.T. Koorevaar

**Appropriate care for orthopedic patients: effect of implementation of the clinical practice guideline for diagnosis and treatment of subacromial pain syndrome in the Netherlands.**

Acta Orthopaedica (2019) 90 (3), 191-195

*Oral presentation SECEC congress 2018, Geneva, Switzerland*

*Oral Presentation Dutch Shoulder Elbow Society Meeting 2018, the Netherlands*

*Oral Presentation, NOF congress 2018, Iceland*

*Oral Presentation, NOV congress 2018, the Netherlands*

*Poster presentation, ESSKA congress 2018, Glasgow, Scotland*

*Poster presentation NVA congress 2018, the Netherlands*

A. Vermeulen, E.B.M. Landman, E.J.D. Veen, S. Nienhuis, C.T. Koorevaar

**Long-term clinical outcome of arthroscopic Bankart repair with suture anchors.**

Journal of Shoulder and Elbow Surgery (2018) 28(5), e252-e258

*Oral presentation, NOV congress 2017, the Netherlands*

*Poster presentation, SECEC congress 2018, Geneva, Switzerland*

A. Brandsma, E.J.D. Veen, R.E. Westerbeek, J.P.W. van Jonbergen

**A case report of osteochondral fracture after an 'acute knee' injury.**

Medisch Contact (2018) 36, 27

E.J.D. Veen, C.T. Koorevaar, R.L. Diercks

**Using the long head of biceps tendon autograft as an anatomical reconstruction of the rotator cable; an arthroscopic technique for patients with massive rotator cuff tears.**

Arthroscopy Techniques (2018) 7 , e699-e703

E.J.D. Veen, C.M. Donders, R.E. Westerbeek, R.P. Derks, E.B.M. Landman, C.T. Koorevaar

**Predictive findings on MRI in patients with symptomatic acromioclavicular osteoarthritis**

Journal of Shoulder and Elbow Surgery (2018) 27(8); e252-e258

*Oral presentation, NOV congress 2016, the Netherlands*

E.J.D. Veen, M. Stevens, R.L. Diercks

**Biceps autograft for rotator cuff tears, a systematic review: techniques and outcome.**

Arthroscopy (2018) 4, 1297-1305

*Awarded by Share research department as "PhD Top Publication"*

M. Bhandari, E. Guerra, J. Bago (Editors) (McMaster University, Toronto, Canada)

**Climbing Mount Evidence: A Practical, Case-Based Approach to Evidence-based Surgery.**

E.J.D. Veen author of book chapter "case series"  
translated in Spanish (2018), ISBN: 9788491101550

S.L. Haak, E.J.D. Veen, R.L. Diercks

**Xrays of acute knee injury, the added value of the lateral femoral notch sign.**

Sport and Medicine, (2017) Vol 2. 32-35

E.J.D. Veen, J.C.M. Schrier, M.J. Breslau, E. van 't Riet, A.F.W. Barnaart

**Outcome of the cementless Zweymüller BICON-PLUS Cup in the very elderly individuals.**

Geriatric Orthopedic Surgery & Rehabilitation (2016) 7(2) 74-80

E.J.D. Veen, R.G. Zuurmond

**Mid-term results of ankle fractures with and without syndesmotic rupture.**

Foot Ankle Surgery (2015) 21: 30-6

*Oral presentation, European Foot Ankle Society congress 2013, the Netherlands*

E.J.D. Veen, F.B. Poelmann, F.F.A Ypma

**A traumatic superficial temporal artery aneurysm after a bicycle accident**

Journal of Surgical Case Reports (2014) 10

*Poster presentation, Dutch Trauma Society 2014, Amsterdam, the Netherlands*

E.J.D. Veen, D.D. Langeloo

**Intermittent pain around the hip**

British Medical Journal (2013) 347: f4972

E.J.D. Veen, R.G. Zuurmond, H.B. Ettema, A.K. Mostert

**Are there any advantages in using a distal aiming device for distal tibial nailing?: comparing the Centro Nailing System with the Unreamed Tibia Nail**

Injury (2011) 42: 1049-1052

*Poster presentation, Dutch Trauma Society 2010, Amsterdam, the Netherlands*

E.J.D. Veen, F.G. Dijkers

**Topical use of MMC in the upper aerodigestive tract: a review on the side effects**

European Archives of Otorhinolaryngology (2010) 267: 327-334

*Oral presentation, Dutch ENT Society 2009, Nieuwegein, the Netherlands*

## RESEARCH INSTITUTE SHARE

This thesis is published within the **Research Institute SHARE** (Science in Healthy Ageing and healthcaRE) of the University Medical Center Groningen / University of Groningen. Further information regarding the institute and its research can be obtained from our internet site: <https://umcgresearch.org/w/share>

More recent theses can be found in the list below.  
(supervisors are between brackets)

### 2021

#### **Hulshof TA**

Quantitative appraisal of trial methods in reviews: an investigation of antipsychotic drug effects in dementia  
(*prof SU Zuidema, dr HJ Luijendijk*)

#### **Broekstra R**

Values of trust and participation in scientific data repositories  
(*prof RP Stolk, prof S Otten, dr ELM Maeckelberghe, dr JL Aris-Meijer*)

#### **Du Y**

CT lung cancer screening in China; the necessity to optimize target population  
(*prof GH de Bock, prof M Oudkerk, dr GA Sidorenkov*)

#### **Gol JM**

Betwixt and between; medical care for functional somatic symptoms  
(*prof JGM Rosmalen, prof ROB Gans, prof RC Oude Voshaar*)

#### **Tegegne BS**

The heart of the matter; discovery of new genetic loci for heart rate variability and its relationship with blood pressure and mortality  
(*prof H Snieder, dr H Riese, dr IM Nolte*)

#### **Vries AM de**

Regaining control during dialysis  
(*prof AV Ranchor, prof GJ Navis, dr MJ Schroevers, dr R Westerhuis*)

**Berg KS van der**

Determinants of adverse health outcomes in late-life depression; the role of vitamine D and frailty

*(prof RC Oude Voshaar, dr RM Marijnissen, dr JM Hegeman)*

**Asefa NG**

Genetics and epidemiology of glaucoma and myopia

*(prof H Snieder, prof NM Jansonius)*

**Kalteren WS**

Neonatal anemia and red blood cell transfusions: finding the optimal balance

*(prof AF Bos, dr EMW Kooi)*

**Elfrink AKE**

Evaluating quality of care in liver surgery; the Dutch hepato biliary audit project

*(prof Jm Klaase, dr DJ Grünhagen, dr NFM Kok)*

**Spahrkäs SS**

Beating cancer-related fatigue with the Untire app

*(prof M Hagedoorn, prof R Sanderman, dr A Looijmans)*

**Slagers AJ**

Beyond the tendon; psychological factors during rehabilitation of lower limb tendon injuries

*(prof J Zwerver, dr I van den Akker-Scheek, prof JHB Geertzen, dr IHF Reininga)*

**Kan K**

Going beyond cost-effectiveness: analyzing routine mental healthcare data and stakeholders' perspectives to improve depression care

*(prof RA Schoevers, prof TL Feenstra, prof E Buskens, dr F Jörg)*

**Ee IB van**

The art of living with cancer at an advanced age

*(prof JPJ Slaets, prof M Hagedoorn, dr CHM Smits)*

**Loohuis AMM**

App-based treatment for female urinary incontinence; evidence based eHealth as an alternative to care-as-usual

*(prof MY Berger, dr MH Blanker, de H van der Worp)*

**Wijnen A**

Rehabilitation policies following total hip arthroplasty; across borders  
(*prof SK Bulstra, dr M Stevens, dr D Lazovic*)

**Narmandakh A**

The night before the day after; connections between sleep problems and anxiety  
across the lifespan  
(*prof AJ Oldehinkel, dr AM Roest*)

**Birkenhäger-Gillesse EG**

'More at Home with Dementia'; effects of psychosocial interventions in the community  
and in nursing homes  
(*prof SU Zuidema, prof WP Achterberg, dr SIM Janus*)

**Sheferaw ED**

Improving respectful maternity care in Ethiopia  
(*prof J Stekelenburg, prof TH van den Akker, dr YM Kim*)

For earlier theses visit our website





Medical School Twente



Dutch **Shoulder**  
and **Elbow** Society



Nederlandse Vereniging  
voor Arthroscopie

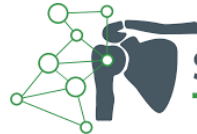

NEDERLANDSE  
ORTHOPAEDISCHE  
VERENIGING | NOV

Anna  
Fonds

Nederlands  
Orthopedisch  
Research en  
Educatie  
Fonds

Deventer  
ziekenhuis



SchouderNetwerk  
Twente

msc  
zorg



fyon

Fysiotherapie Oost Nederland

ChipSoft





*Research Institute*

**SHARE**